# EYE

Junc$^{n}$ of cornea & sclera → LIMBUS

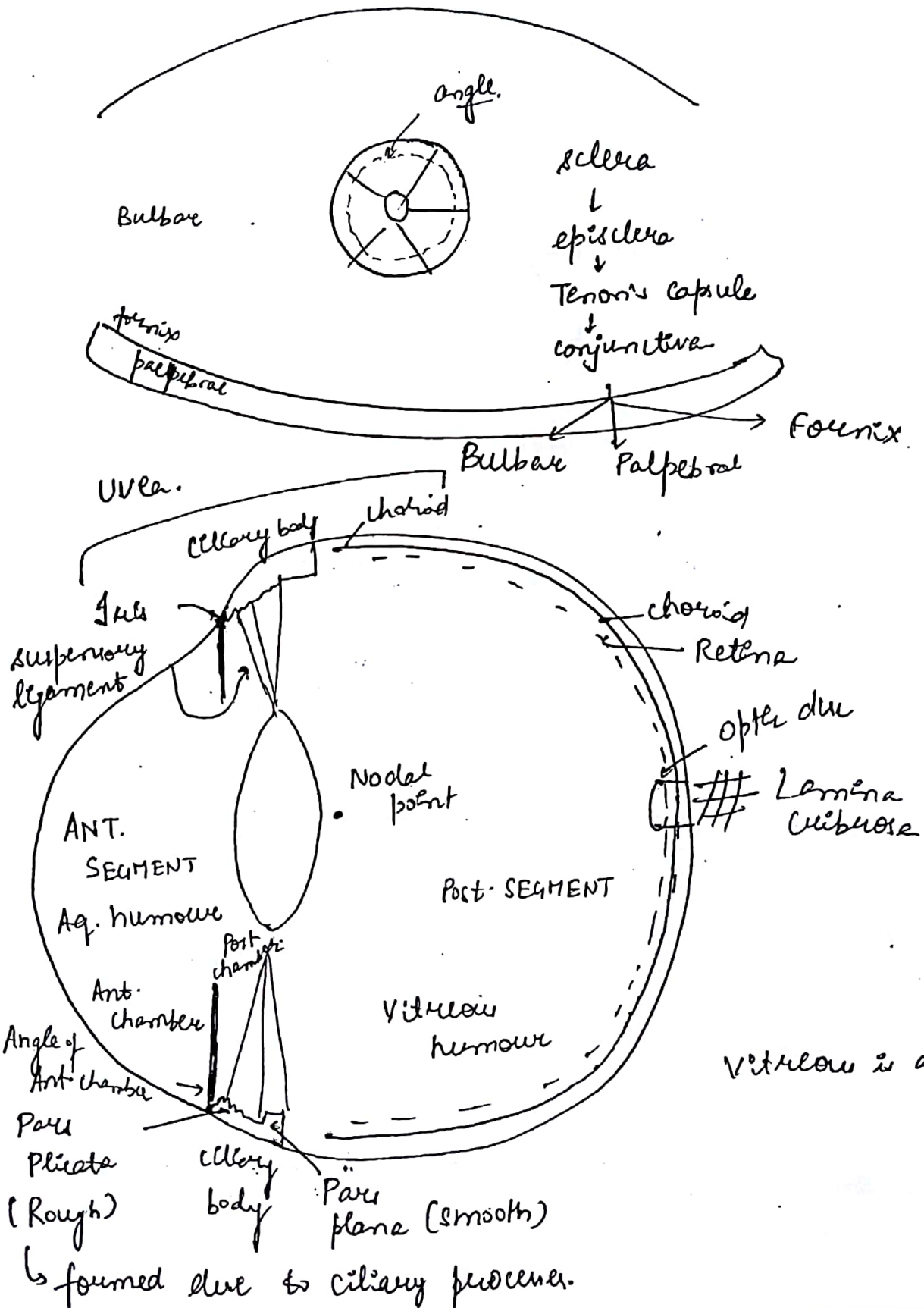


Vitreous is a gel.

↳ formed due to ciliary processes.

## TRABECULAR OUTFLOW

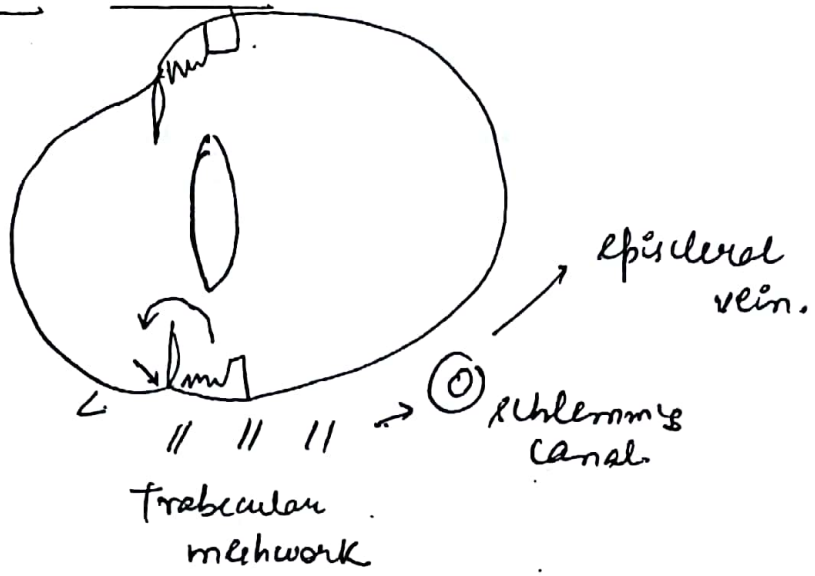


Q. Total no. of ciliary process → 70-75.

Q. Angle is all around 360°, corresponding to limbus.

## NODAL POINT

- Parallel light rays falling on the cornea & lens, ~~image is~~ so rays are focussed on nodal point
- It is the 1st focal point situated just behind the lens
- Bending of light is more on cornea as compared to lens.

  * factors

  ① curvature of cornea
  more is the curvature, more is the refractive power

  ② difference of refractive index between air & water.

Q. What is the most imp. factor to focus light rays on retina?

ans. curvature of cornea → [ant. surface].

Q. Why is the vision less when water is present in eye?

ans becoz media is water + water

↓

less bending of light

↓

loss of refraction.

Cornea & lens are avascular. as they need to be transparent

They receive nutrition from aqueous humour

OPTIC DISC

- The part where all the nerves aggregate.
- Sclera here is sieve like ⇒ Lamina cribrosa.

Q. IOP - 10-21 mm Hg

# RETINA



Nasal Part

ora serrata

Temporal Part

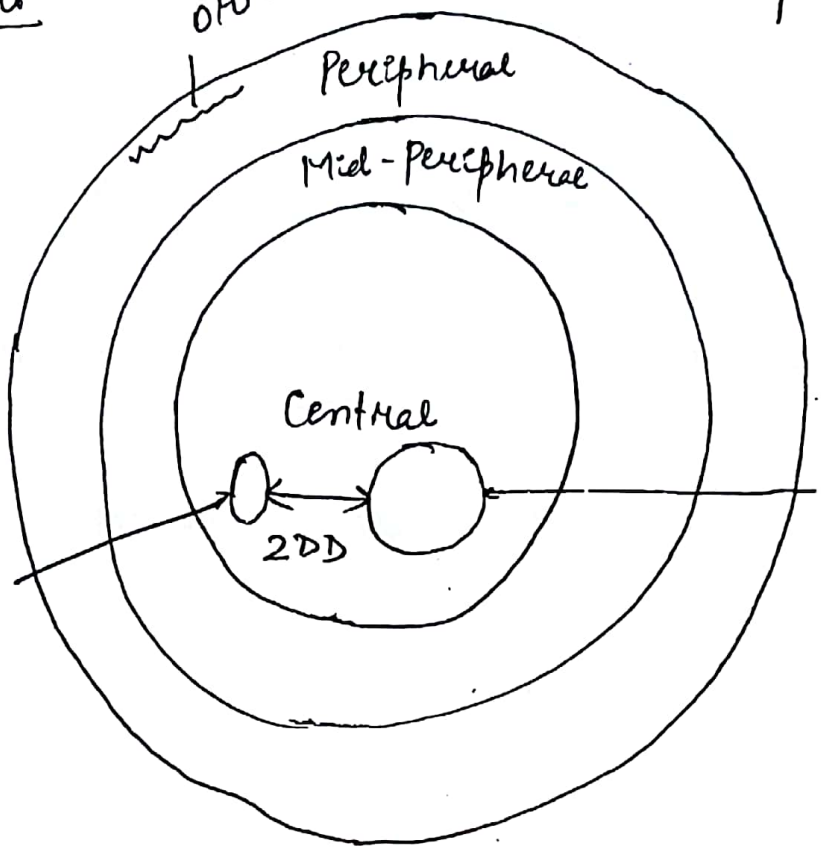


central retina

Macula
(5-5.5mm)

Optic disc
(1.5mm)

Central Vision → macular func" → tested by **Snellen's Chart**

Peripheral Vision → peripheral retina → tested by **Perimetry**

Scotoma -
An area in the visual field where the patient is not able to see.

Blind Spot -
Physiological scotoma corresponding to optic disc
↳ Temporal to macula.

Isopter -
Different axis on which we test peripheral vision on perimetry.

# MACULA

D → 5 – 5.5 mm

*Most sensitive part of Retina.

↓

FOVEA.

(foveola is given in option becoz cones are found max. there)

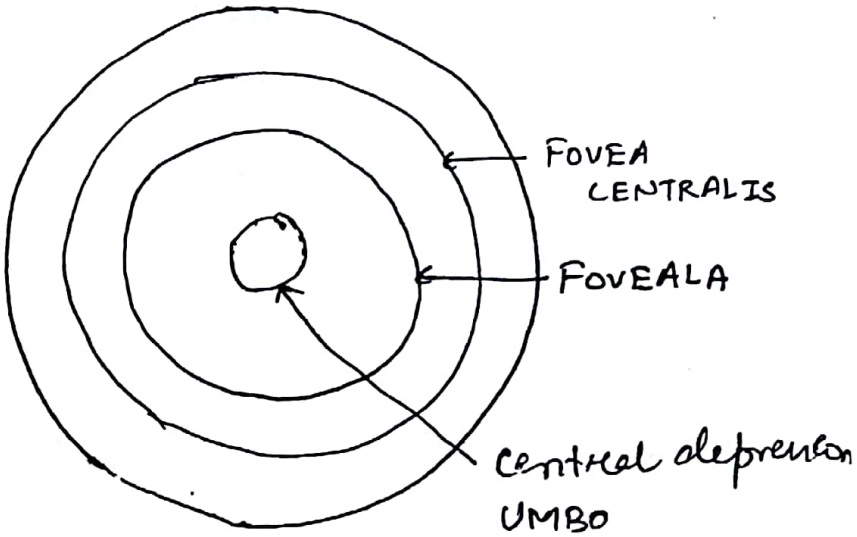


Thinnest part of Retina ⇒ $\boxed{\text{Orra Serrata}}$

Distance Betn Optic Disc & Macula ⇒ 2DD = 3mm.

Most radio Resistant Layer of retina → Ganglion cell layer

Most radio sensitive layer → Rods & cones

# ORBIT

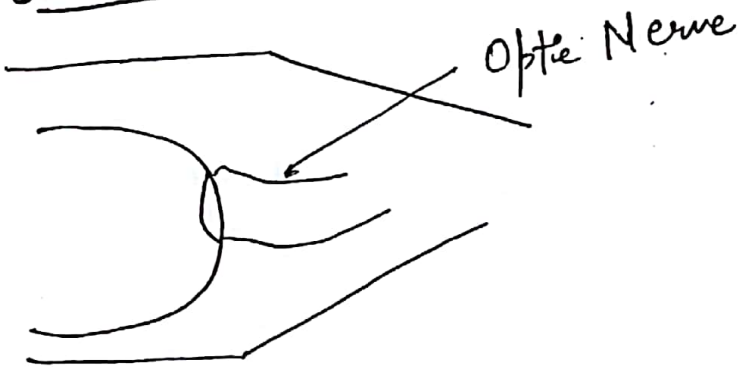


Capacity of Orbit = 30 cc

Shape of orbit = Quadrilateral or Pyramidal

Length of Optic Nerve = 3.5 cm - 5.5 cm. [5 cm]

Axial Length of eyeball = 24 mm.
[Antero-posterior diameter].

## USG

- A Scan → for measuring antero-posterior diameter
- B Scan → for post. segment of eye

Depth of Ant. Chamber = 2.4mm - 2.5mm.

(2.5)

## Anisometropia

difference of refractive power between the 2 eyes of > 2.5 diopters

- Y Infant is hypermetropic.

2.5 - 3 Diopters due to small eye.

## HYPERMETROPIA

Total refractive power of eye is less than required

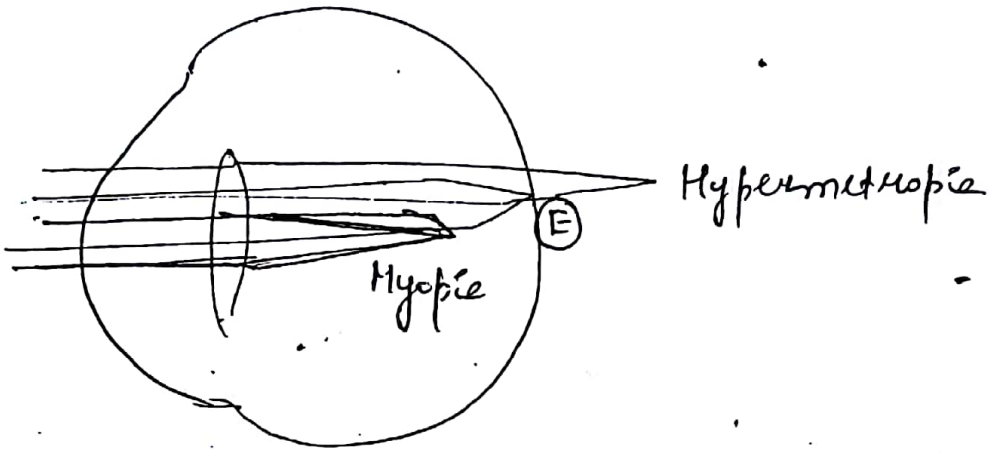


- Small eye
- Light rays are focussed behind the retina
- To correct the error ⇒ CONVEX LENS Used. (+)

## MYOPIA

- Total Refractive Power is more than required
- Large eyes
- Light rays are focussed in front of retina.
- To correct the error ⇒ CONCAVE LENS used. (−).

# ASTIGMATISM

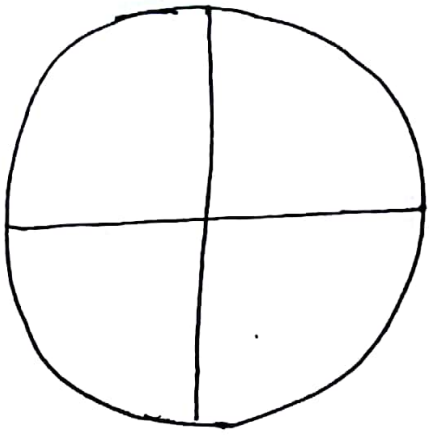

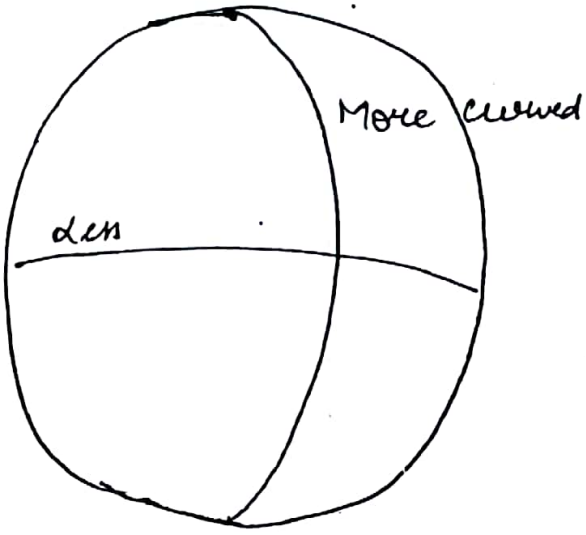


Difference of refractive power between 2 principal axis

# REFRACTION

- Total Refractive Power of Eye = 58-60 D.
  or
  Reduced eye

- Reduced Eye:-
  Simplified optical system of eye

- Refractive Power of Cornea → 43-45 D Q
- " " " Lens → 16-17 D. Q.

- Refractive Index of cornea → 1.37 Q.
- " " " Lens → 1.39 Q.

- Maximum Refractive Index → @ centre → 1.4-1.41



## RETINOSCOPY -

- Objective method of refraction.

## FUNDOSCOPY -

- for ~~mean~~ retina fundus is synonymous.

PAPILLA - for optic disc.

QQ OPHTHALMOSCOPE.

| DIRECT | INDIRECT |
|---|---|
| Magnification = 15 times | 5 times. |
| Image → Virtual, Erect | Real, Inverted |
| Area/Field - 2 DD | 8 DD. |
| Used for Central Retina | Peripheral Retina + Central Retina (but magnification is less) |

Distant Direct Ophthalmoscopy :-

for viewing media

↓

all the str. ⊆ comes in the way of light



Distance for DDO = 25cm

∁ Lenticular opacity is best seen by DDO
= Post. Subcapsular Cataract

## CORNEA

Shape – aspheric
curvature is gradually ↓



Diameter – 11-11.75 mm

Megalocornea >13mm.
Microcornea <10mm [adult].

## LENS

shape – BiconvEx

Diameter – 9-10 mm [9].

Microphakia – small lens.
<9mm

Microspherophakia – small spherical lens

Aphakia → absence of lens

Pseudophakia → artificial IOC

# DISEASES OF LENS

Power - 16-17D

Refractive index - 1.39.

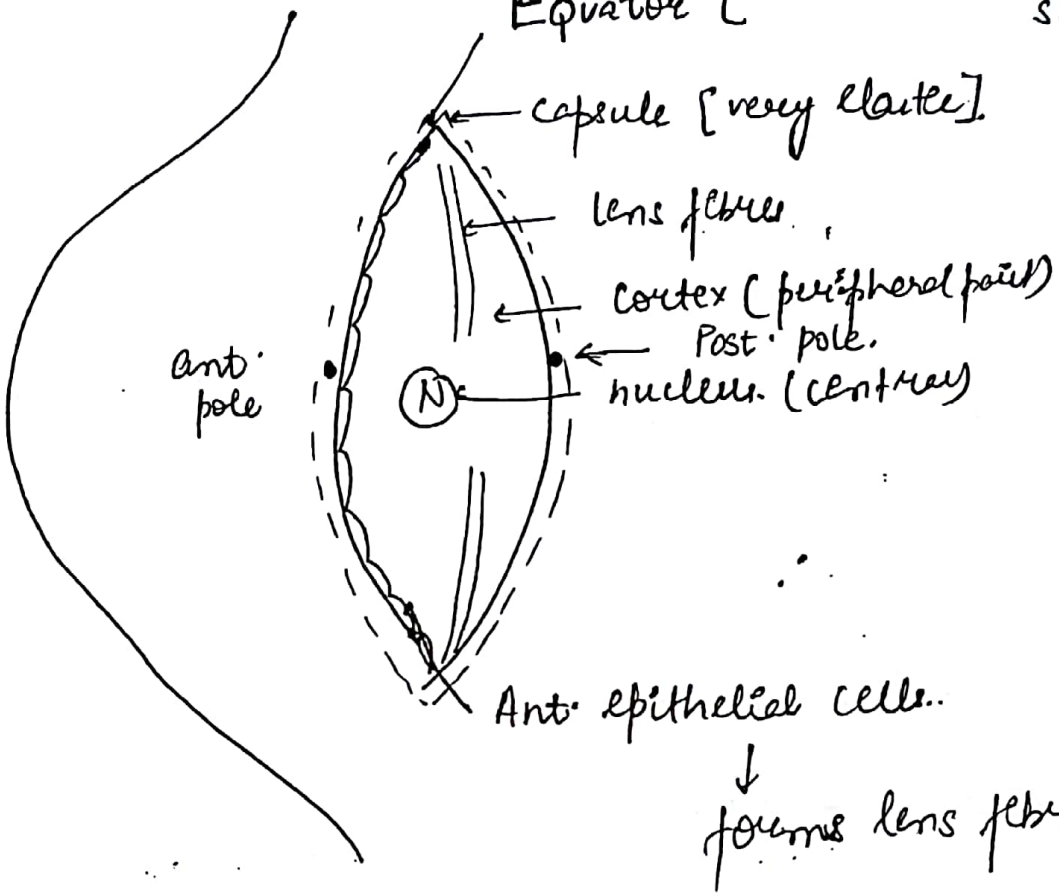


Q. ☾ is the thinnest part of Lens
↳ capsule at posterior pole [thickness 4μ].

Q. ☾ are the youngest fibres - Cortex

Q. Till what time period lens fibres are formed → throughout life.

# PHYSIOLOGY

- Avascular
- Dehydrated [lens maintain this by Pump leak mechanism]

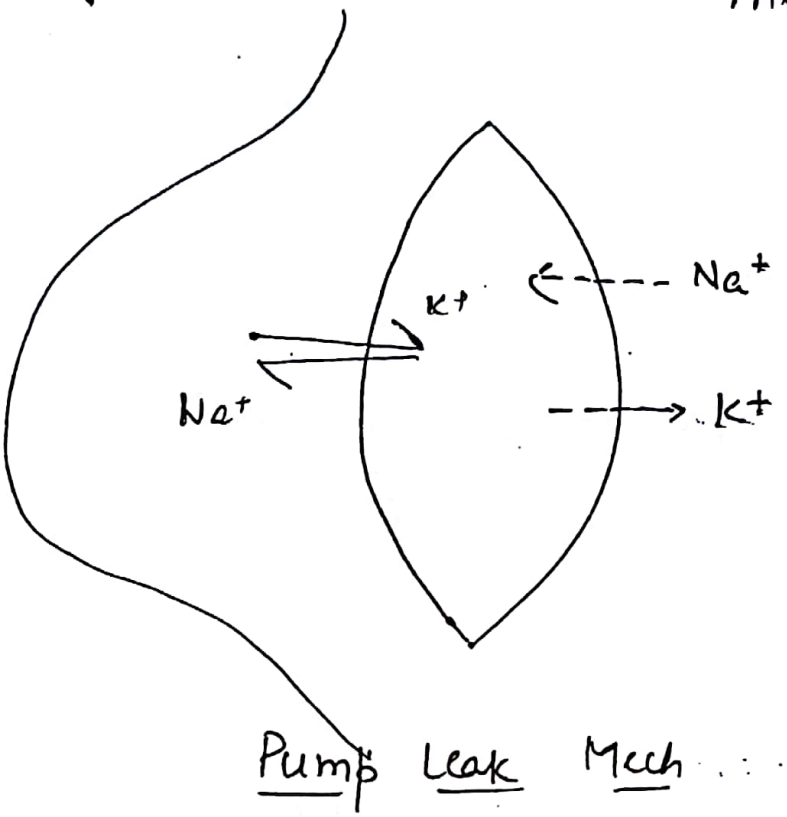


Pump Leak Mech.

Q 1° Metabolism = Anaerobic [80% of glucose metabolised anaerobically]

- Lens derives its nutrition from Aqueous Humour only.
- Lens is derived from Surface Ectoderm.

HM3 & HM4 are insoluble high molecular wt proteins found in CATARACTOUS LENS.

# EMBRYONIC DEVELOPMENT



## SURFACE ECTODERM

① Epithelial Lining of Cornea + Conjunctive
② " " " Lacrimal Gland
③ Lens Q.
④

## NEUROECTODERM

① Retina
② Optic ~~Cup~~ Nerve
③ Epithelial Lining of Iris + Ciliary Body Q
④ Smooth M/s of Iris → ① Iris sphincter Q.
② Dilator Pupillae

⑤ 2° & 3° vitreous Q.
↓ adult ↓ suspensory ligament

## NEURAL CREST

1) Sclera except temporal part
2) Choroid
3) Corneal Stroma Q
4) Corneal endothelium Q
⑤ Ciliary M/s Q.
⑥ Trabecular Meshwork

## MESODERM

① Temporal Part of sclera
② EOM.
③ Blood vessels.
④ 1° vitreous Q.
↳ vitreous during embryonic period

## CATARACT

Any opacity in lens or its capsule ∠ hinders its optical homogenity

### Classification

- CONGENITAL/ DEVELOPMENTAL
- ACQUIRED

## CONGENITAL CATARACT

Etiology - ① TORCHS Infection
② Radiation exposure in 1st Trimester
③ Teratogenic Drugs eg Thalidomide
④ Malnutrition
⑤ Anoxia

## Types

1) BLUE DOT CATARACT-
Opacities are seen as Bluish Dots.

2) CATARACTA PURVULENTA-
Opacities are powdery

3) LAMELLAR/ZONULAR CATARACT-
single lamella is cataractous.

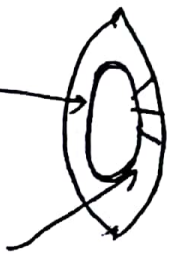

Additional spoke like opacities.
over the cataractous lamella → RIDERS
Vit D deficiency causes Lamellar Cataract
Rubella infection also causes.

4) Ant. POLAR CATARACT

5) Post. POLAR "



5) TOTAL CONGENITAR CATARACT

Q. M/c type of congenital Cataract - Blue-Dot

Q. M/c type " " causing diminition of vision
- Lamellar.

# CONG. RUBELLA SYNDROME

CHD

Cataract → M/c type
1) Nuclear Pearly
2) Lamellar.

Heart Defects

Deafness

* Ocular Features of Rubella :-

1) Micro-ophthalmos
   → Any axial length of eyeball < 21 mm. or 1 year of age < 19 mm.
2) Rubella Keratitis.
3) Angle anomaly leading to Glaucoma
4) Nuclear Pearly Cataract
5) Salt & Pepper Fundus.
   ↳ pigmentary disturbance of retena due to diffuse chorio-retinitis.

## D/D of Salt & Pepper Fundus

1) Rubella
2) Syphilis
3) Retinis Pigmentosa sine pigmento

④ Myotonic Dystrophy
↓
Type of cataract ⇒ Christmas Tree.

⑤ Leber's Amaurosis

Amaurosis :- Total Loss of vision.

Amblyopia :- Partial Loss of vision

Amaurosis Fugax :- Transient loss of vision.
↓
curtain like manner.

# ACQUIRED CATARACT

CLASSIFICATION

Anatomically

A/c to maturity

Etiology

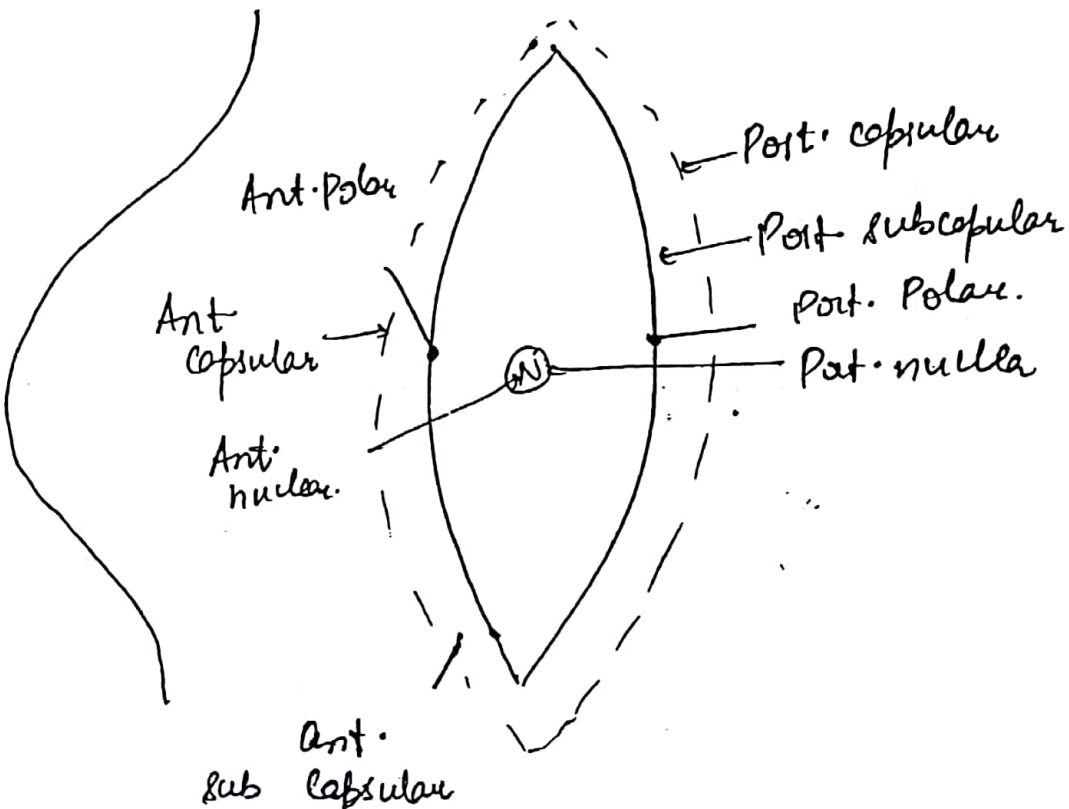

@ Cataract will ↓ vision most = post subcapsular.
↓
as it is near to the nodal point.

* A/c to Maturity -

1) Immature 

2) Mature 

3) Hypermature
- degenerative changes int
- wrinkling of capsule occurs
- liquefaction of cortex


wrinkling of capsule

* Etiological classification

1) Senile → M/C
2) Metabolic
3) Complicated
4) Toxic
5) Traumatic
6) Radiational

# SENILE CATARACT

## CORTICAL

Etio - Hydration

C/F

I - Stage of Lamellar separation.

II - Stage of Incipient Cataract [Immature cataract]
little hydration

III - Stage of Intumescent Cataract
(max. hydration)

IV Mature Cataract

V Hypermature/ Morgagnian Cataract
↓
M/c Complication
↓
PHACOLYTIC GLAUCOMA

## NUCLEAR

Etio - Nuclear Sclerosis
↓
Insoluble protein deposition

Pigment Deposition.
↓
Melanin  Urochrome Q

I. Immature

II. Mature

III. Hypermature or Nuclear Sclerotic Cataract
↓
M/c complication QQ
↓
Subluxation of Lens.
(Partial dislocation)

## Phacolytic Glaucoma

Leakage of Lens protein in the aqueous

↓

Block TMW.

↓

Leading to Glaucoma

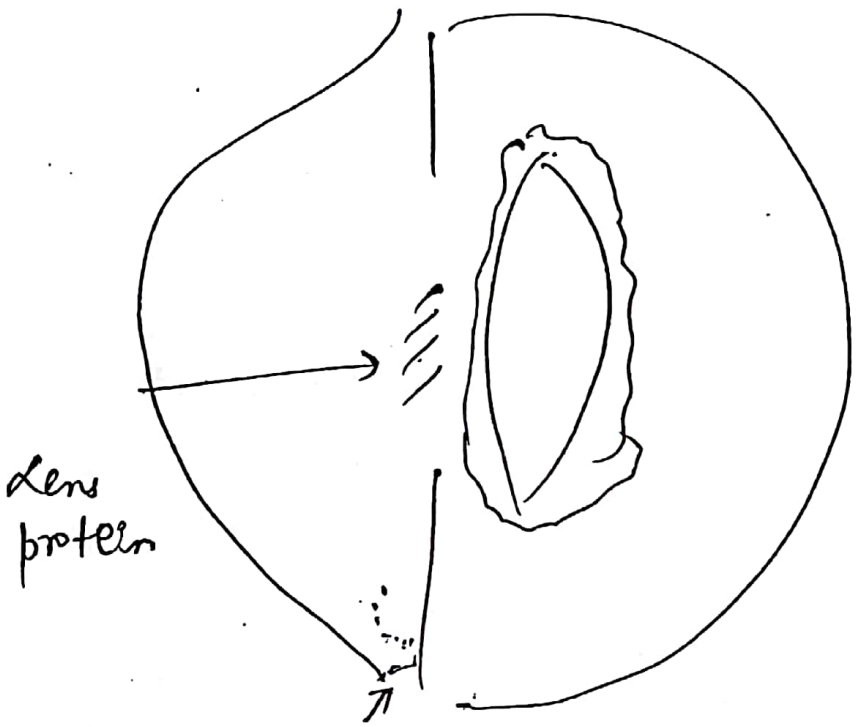


Block TMW ⇒ Glaucoma

Radial Spokes ⇒ Seen in Cortical Cataract

also k/n/a Cuneiform cataract

Cupuliform Cataract - Post Subcapsular Cataract

**II^nd Sight Of Old Age :-**

- Improvement in near Glasses.
- occurs due to nuclear sclerosis in early stage

# ACCOMODATION



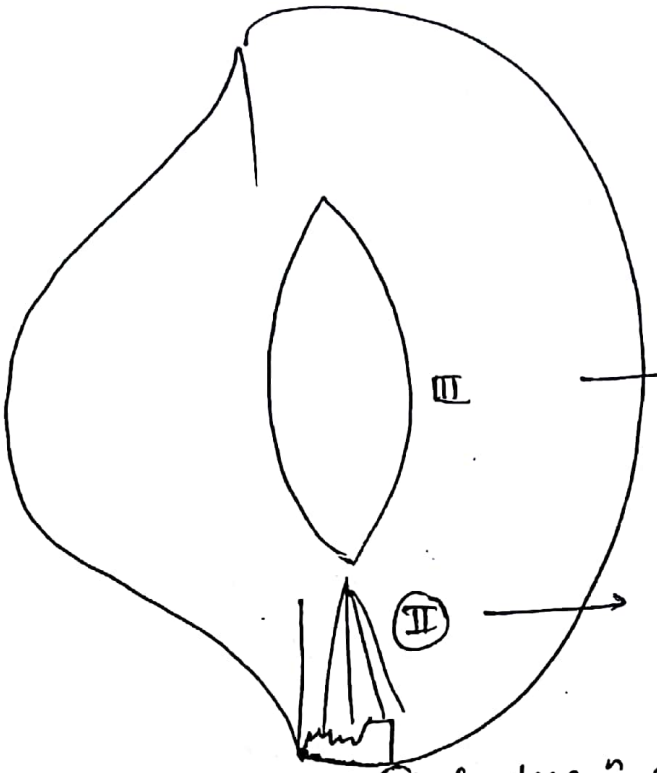


III → Curvature ↑ ⇒ More refractive power.

II → Relax^n of zonules

I Contrac^n of ciliary M/s

## AGE RELATED CHANGES

1> Weakening of ciliary M/s

2> Less elasticity of Lens..

↓

PRESBYOPIA – error of accomodation.

Sets at the age of 40 yrs.. [≥ 40 yrs]

Presbyopic glasses [Near Glass]

↓

CONVEX LENS.

# METOBOLIC CATARACT



## (I) DIABETES

Cause - Accumulation of Sorbitol.

↓

Hyperosmotic nature

↓

Imbibe $H_2O$

⇓

CATARACT

Enzyme responsible for sorbital Pathway -
NADPH dependent aldose reductase.

Type of Cataract ⇒ Snow flake or Snow storm Cataract

↓

More common in **Type-I DM**

## (II) GALACTOSEMIA [Reversible Cataract] Q

↓

Galactokinase deficiency

⇓

LAMELLAR CATARACT

↓

GPUT (Galactose phosphate uridyl transferase)

⇓

Q. OIL-DROPLET CATARACT

## (III) CHALCOSIS

- Cu containing F.B. → SUNFLOWER CATARACT.
- Wilson's Disease → K.F. Ring. (on cornea)

Cu deposited on Descemet's membrane

- Reversible

### FLEISCHER'S RING

- seen in pts. of Keratoconus.
- occurs due to Fe deposition
- Deposition on Epithelium




## (IV) LOWE'S SYNDROME / OCULO-CEREBRO RENAL SYNDROME

Ocular features

(A) LENS

1) Microphakia
2) Metabolic Cataract
3) Posterior Lenticonus

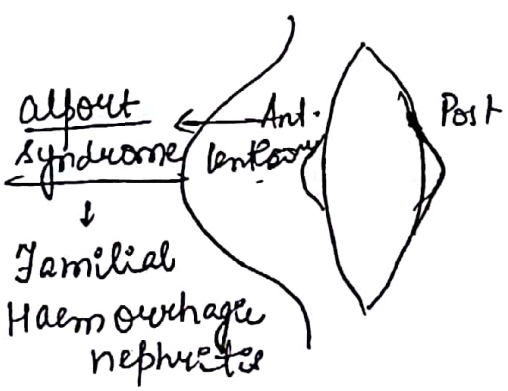


(B) GLAUCOMA-

Ant. Lenticonus → Oil-globule reflex +ve
is more common in ♂

1) Alport's syndrome
2) Waardenburg Syndrome

a) Telecanthus - medial canthus are far apart
b) Poliosis - Greying of eyelashes
c) Heterochromia Iridis (HI)
Difference of iris colour between 2 eyes
d) Anterior Lenticonus

---

| TELECANTHUS | HYPERTELORISM |
|---|---|
| • Soft tissue problem. | • Bony Defect |
| • Interpupillary Distance (N) | • Interpupillary Distance ↑ |

## COMPLICATED CATARACT

Cataract is occuring as a complication of ant. + post segment disease

C/F -

1) Polychromatic Lusture
2) Bread crumb appearance of opacities.
3) M/c type ⇒ Posterior subcapsular

## TOXIC CATARACT

Due to Drugs.

1) Steroids
2) Phenothiazines
3) Long acting Miotics
4) Amiodarone
5) Busulphan
6) Gold
7) CQ.

Ant. sub capsular → Post. sub capsular Cataract

M/c comp$^{n}$ of steroids in eye ⇒ Glaucoma (OAG - open → blockage in TM ↓)

Steroid
- Systemic → Cataract (PSC)
- Topical → Glaucoma

# TRAUMATIC CATARACT

Trauma

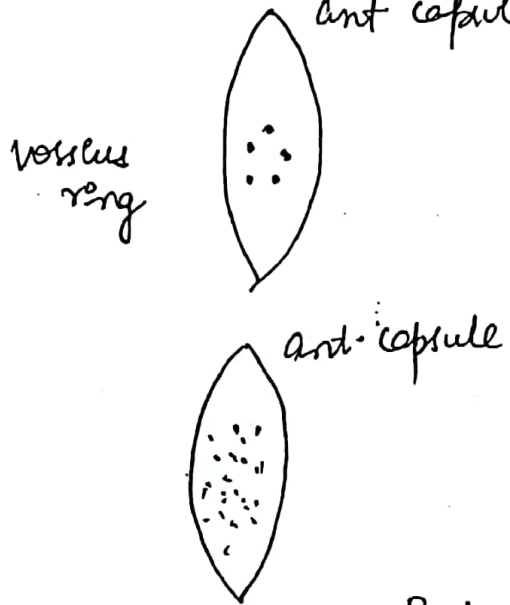

- Perforating
  - (→O)
- Blunt
  - OO (concussion injury).
  - Rosette shaped or Sunflower cataract
  - Vossius Ring
    - Imprint of Iris pigment in shape of Pupil on the ant. capsule of lens.
    - ant capsule of lens
    - vossius ring
    - ant. capsule
    - Glaucoma flecken → Past H/O attack of acute congestive Glaucoma
  - Berlin oedema or Commotio Retinae
    - Oedema at the macula
    - CHERRY RED SPOT
  - Angle recession glaucoma
    - Due to tear in ciliary body
    - Damage to TMW.
    - Glaucoma

# RADIATIONAL CATARACT

1) All electromagnetic radiation can cause Cataract
   CT Scan ✓
   MRI ✗

2) M/c type of radiational Cataract ⇒ Post. subcapsular

## PSC

1) M/c type of complicated Cataract
2) " " " radiational "
3) steroids causes
4) C type of cataract ↓ vision most
5) C type of cataract is best seen by DDO

Most radioresistant in Eye → sclera
Lens
Most radio sensitive " "

Retina < most radio resistant ⇒ Ganglion cell Layer
" " sensitive ⇒ Rods & Cones

## C/F of cataract :-

1) Blurring of vision

(E) → 5/minute

2) Diminution of vision

Vision < 6/6

Denominator is normal

- All letters form an angle of [5 minute] at nodal point
- Margin of every letter subtend an angle of [1 minute]

3) Glare

4) Polyopia

→ 2 images.

- Incipient cataract (✓) (More)
- Intumescent Cataract

5) Coloured Haloes

Breaking of white light

Causes

- CATARACT
- ACUTE CONGESTIVE GLAUCOMA
  - ↓
  - IOP ~ 60 mm Hg
  - ↓
  - Corneal edema
  - ↓
  - lead to coloured Haloes
- MUCOPURULENT CONJUNCTIVITIES
  - ↓
  - causes diffraction of light

## Fincham's Test :-

- Test to differentiate Between coloured halos of Cataract & Acute Congestive Glaucoma
- Passing a stenopic slit in front of eyes

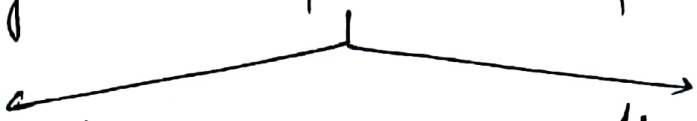

If halos break → CATARACT

If not break → Acute Congestive Glaucoma

## T/t

### SURGICAL

(I) ICCE [Intra capsular Cataract Extraction]

↓

Removal of lens including capsule

### METHODS.

a) Forceps Extraction.
By Arruga's forceps.

b) Cryo extraction
-40°c temp.
lens sticks to the probe & can be taken out.

c) Wire Vectis Method.



d) Indian Smith Method.
pressure & counter pressure method.

Only Indication ⇒ Subluxation of lens

Best Method ⇒ Cryoextraction

C/I in children

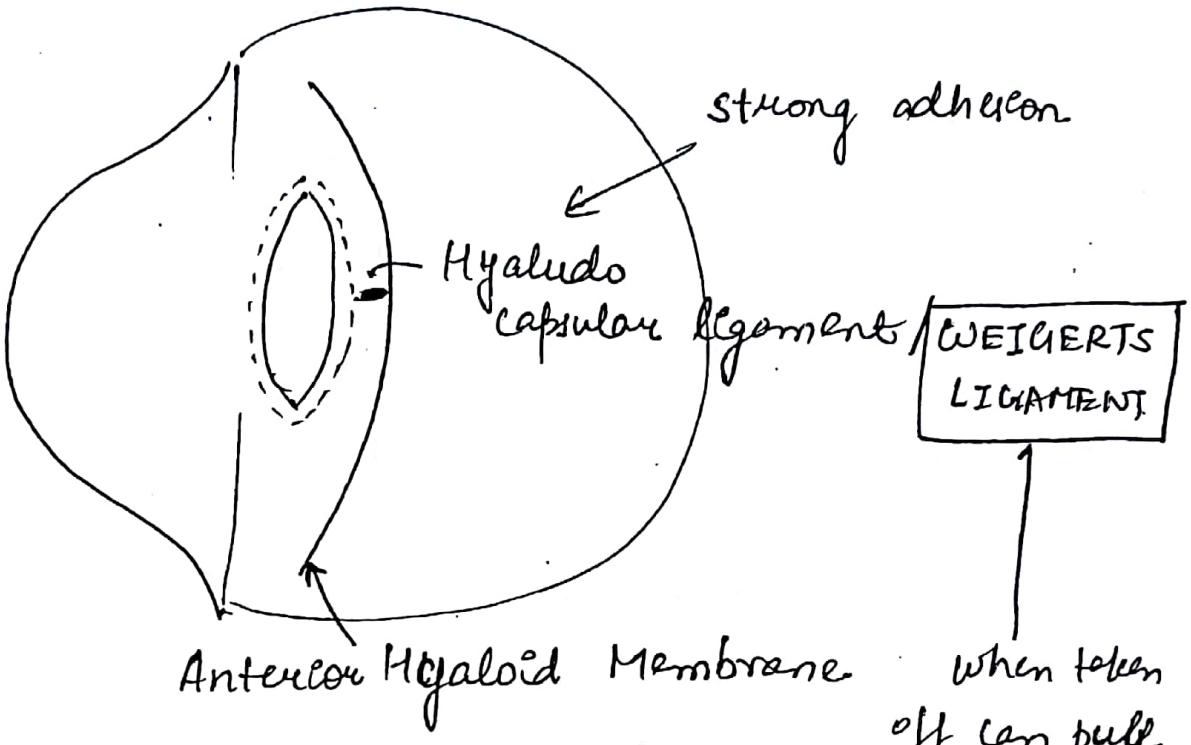


(II) ECCE + PCIOL Implantation.




– Capsular Bag.

↓

IOL is implanted.



IOL is formed of PMMA (Poly Methyl Metha Acrylate)

METHOD

Full thickness scleral incision




↓

Ant. capsulotomy

↓

$H_2O$ injected under the margin

↓

Hydrodissection.

↓

Removal of nucleus by pressure, counter pressure

↓

Clean the bag c̄ irrigation, aspiration.

↓

IOL Implantation

↓

Suture the section by radial sutures.

[equal length, equidistant]

⇓

Less astigmatism post-op.

(III) SICS (Small Incision cataract surgery)

- small incision
- sutureless surgery

## Manual

5 - 5.5 mm

↓

Partial thickness incision

↓

Scleral Tunnel formation.

↓

Capsulotomy

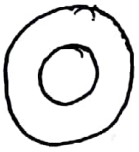

Continuous Curvilinear Capsulorrhexis

[the type done in SICS]



Can-opener technique

↓

Hydrodissection

↓

Remove nucleus

↓

Clean the bag

↓

IOL implanted

↓

NO SUTURES REQUIRED

## Phacoemulsification

2.75 - 3.2 mm. Q

↓

Incision on cornea

[Clear Corneal Incision]

↓

CCC

↓

Hydrodissection.

↓

[for confirmation rotate the lens.]

↓

Phacoprobe

[frequency - (40 kHz) Q.
Break nucleus into bits & aspirate simultaneously]

↓

Clean bag

↓

Foldable IOL used

↙ ↓ ↘

Acrylin — Silicon — Hydrogen

↓

M/c ly used.

(IV) MICS [Minimal Incision Cataract Surgery].

By Phacoemulsification - length of incision 1.8 - 2.4 mm

(V) PHACONIT

Incision length - 0.9 mm.

↓

Rollable IOLs [Acrylic].

(VI) FEMTOLASER Most Recent

Infrared.

$\lambda$ = 1052 nm.

Pulse Duration - $10^{-15}$ sec Q.

## BIOMETRY

Method of calculating Power of IOL

- Axial length by USG.
- Keratometry 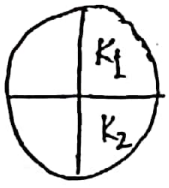

~K.

SRK formula - Power = A - 2.5L - 0.9K.

where A = constant

L = Length axial

K = Keratometry K

Foveal Reflex formation / Fixation Reflex / Macula Maturation.

↓

form by 5-6 month of age

↓

Operate as soon as possible

↓

To prevent amblyopia

↓

also nystagmus develop..



T/t of choice in cong. cataract ⇒ Lensectomy + Vitrectomy (Phaco + ECCE)

## AFTER CATARACT / 2° CATARACT / POST. CAPSULAR OPACIFICATION

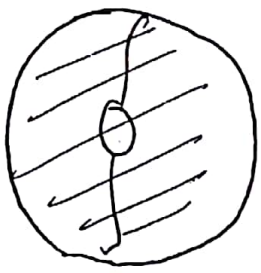

Diffuse opacification.

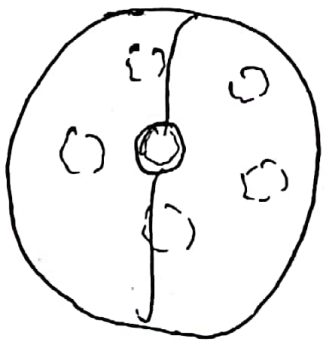

Migrated ant. epithelial cell. [ELSCHNIG PEARLS]

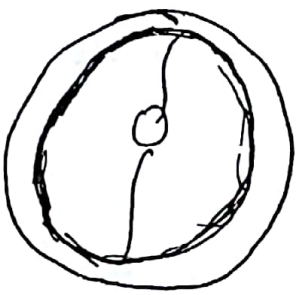

Fibrotic Ring [SOEMMERING RING] ⇓ Vision not affected

Management :- Post. Capsulotomy through NdYAG Laser

# SUBLAXATION OF LENS

Congenital ⇒ ECTOPIA LENTIS

- Simple Ectopia Lentis → only ectopia lentis
- Ectopia Lentis et pupillae → Pupil is displaced in opp. direction + Ectopia Lentis.
- Ectopia Lentis associated with syndrome

MARFAN'S SYNDROME
M
Superio temporal ectopia

Homocysteinuria
H
Infero-nasal

Weil Marchesani
① Downward & forward
② Microspherophakia

Ehler Danlos
① Ectopia lentis
② Blue Sclera (thin sclera)

Ocular features of Marfan :-

1) Axial Myopia
2) Megalocornea → Most prominent feature
3) Supero-Temporal Ectopia Lentis → Most common
4) Lattice Degeneration.
5) Retinal Detachment

# LASERS IN EYE

## Photo-Disruptive

1) NdYAG

* Indications -

a) After cataract

b) Peripheral iridotomy (PI)

2) FEMTOLASER

Cataract surgery

Refractive surgery

↓

Keratomileusis

↓

changing curvature of cornea.

Age. > 18 yrs

## Photo-Coagulative

1) ARGON

2) DIODE

3) Double frequency NdYAG.

### Indications

a) vascular pathologies of retina

b) Trabeculoplasty

## Photo-ablative

1) Excimer

eg Argon Cl

Argon flouride

Xenon Cl/flourid

→ used in eye.

### Indication

Refractive $S_x$

## WAVELENGTHS

1) NdYAG - 1064 nm (Pulse Duration - $10^{-9}$ s)

2) EXCIMER - 193 nm.

3) ARGON - 514 nm.

4) DIODE - 780 - 850 nm.

5) Double frequency NdYAG - 532 nm.

6) FemtoLaser - 1052 nm. (Pulse Duration - $10^{-15}$ s)

# FemtoLaser

## LASIK

- To raise a flap containing epithelium + little bet of strome (cornea). by femtolaser

## SMILE Procedure [small Incision Lenticule extraction)

- No need to raise a flap
- Focus on Strome + cut small part of strome
- Give incision (small) + remove the lenticule (strome).

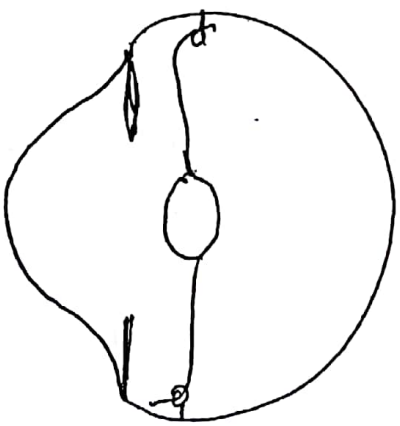

Scleral Fixated IOL [when post. capsule not int]

# GLAUCOMA

## *FORMATION OF AQUEOUS HUMOUR -

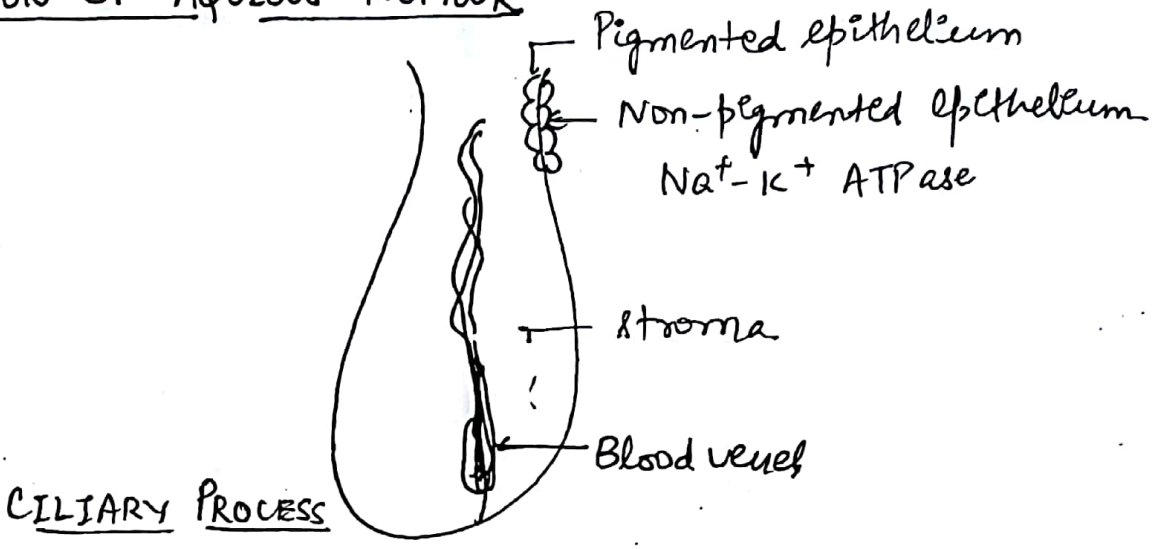


Non-pigmented epithelium is the site of aqueous formation.

### Process

1) Secretion [Max. aqueous is formed by this]
2) Diffusion
3) Ultrafilteration.

Rate of formation of aq. humour = 2-3 µL/min.

Hypersecretory Glaucoma ⇒ When more formation of AH.

↓

Due to Epidemic Dropsy. [TOXIN- SANGUINARINE]

# OUTFLOW OF AQUEOUS

## CONVENTIONAL [90%]

PC
↓
Pupil
↓
AC
↓
Angle [cornea - Descemet's ↳ Schwalbe's line]
↓
TMW
↓
Schlemm's Canal
↓
Episcleral Vein

## UVEO-SCLERAL [10%]

Directly crosses uveal tissue + sclera

## TYPES

### ANGLE CLOSURE

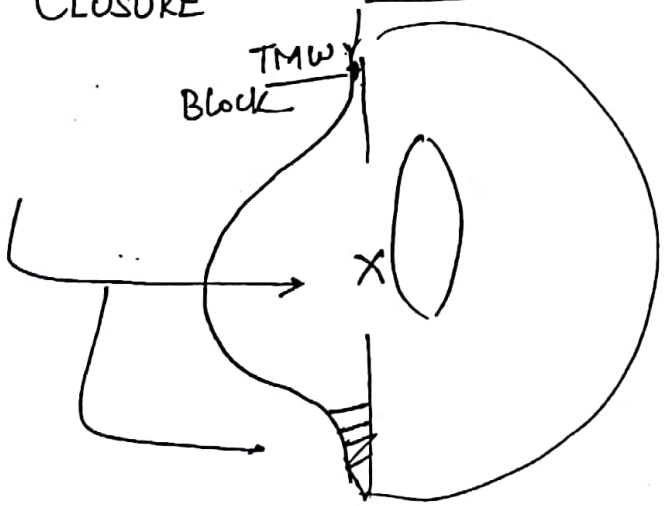


Obstruction at the pupil or actual obliteration of ∠.

### OPEN ANGLE

More common

Block in Trabecular Meshwork

**Def$^{n}$:-** Glaucoma is multifactorial optic neuropathy associated c risk factors like increase IOP, +ve family history.

## CLASSIFICATION

- CONGENITAL / DEVELOPMENTAL
  - True congenital
  - Infantile (< 3 yrs of age)
  - Juvenile (3 yrs to adolescents)
- ACQUIRED.
  - OAG → 1° 2°
  - ACG → 1° 2°

1° - idiopathic

2° - cause known

BUPHTHALMOS

Due to enlargement of eyeball

## 1° CONGENITAL GLAUCOMA

Etiology - 1) Trabecular Dysgenesis

2) Ab (N) Iris Insertion ⇒ FLAT IRIS / PLATEAU IRIS

3) Barkan's Membrane at the angle

C/F -

1) Watering
2) Photophobia - intolerance to light
3) Blepharospasm

O/E

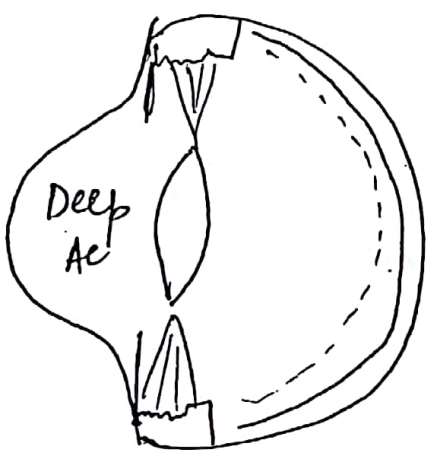


① Large cornea

② White cornea
due to corneal oedema

③ Haabs striae -
break in Descemet's Membrane

④ Iridodonesis -
Tremulousness in IRIS is due to loss of support from lens.

⑤ Flattening of Lens
⑥ Break in suspensory ligament ⇒ Subluxation of Lens

D/D - Megalocornea

⑦ Angle anomaly may be +nt :
⑧ Cupping of disc

T/t of choice

1) GONIOTOMY
Cutting through the angle [Trabecular meshwork].

Trabeculotomy :- cornea when Hazy, Goniotomy can't be done
Cut in TMW & Schlemm's canal

CUPPING OF DISC

Ⓝ Optic Disc has central Pale area ⇒ CUP AREA
The area beside the CUP is Neuro-retinal Rim.

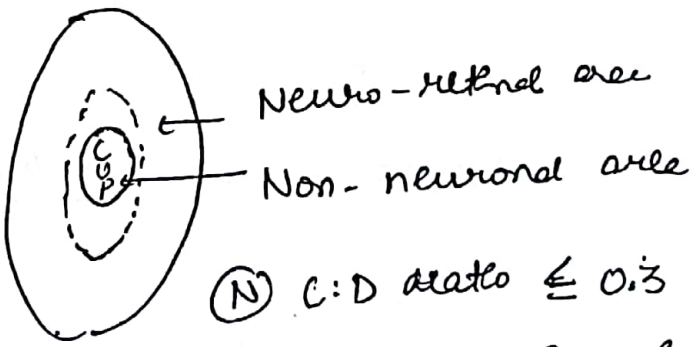


Ⓝ C:D ratio ≤ 0.3

When C:D ration ↑ ⇒ Cupping.

Cupping ⇒ neuronal area is getting damaged
Non-neuronal area is increasing.

In case of glaucoma cupping is vertically oval due to damage to arcuate fibres.

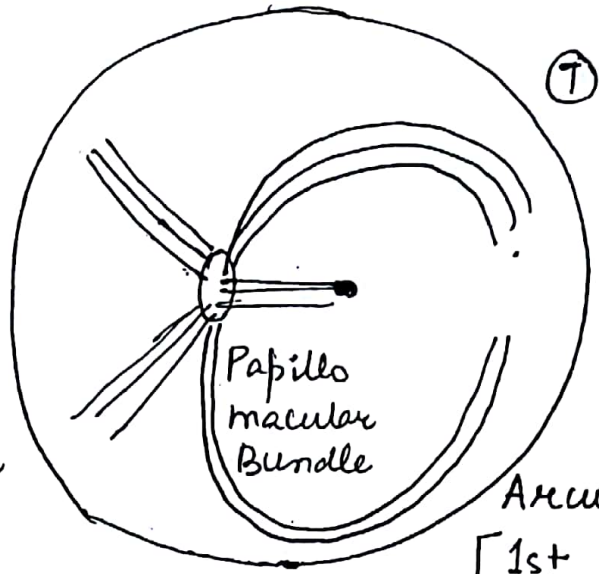


Sup. radiating fibres

Inf. radiating fibres

Arcuate fibres.

[1st Damage in Glaucoma occurs in arcuate fibres]

⇓

1st Field Defect seen in

**Bjerrum's Area**

## BJERRUM'S AREA

Area in the visual field where 1st scotoma appears corresponding to arcuate fibres

## Physiological ~~Glaucoma~~ Cupping

① Horizontally round cup

② B/L symmetrical [Glaucoma is never B/L symmetrical.]

## 2° CONGENITAL GLAUCOMA

① ECTROPIAN UVEAE

Iris pigments everting from pupillary border

② Naevus of Oculodermal melanosis

subepithelial conjunctival melanosis

Associated ∈ angle Anomaly

③ Nano-Ophthalmos
Very small eye
lens size may be normal
No other structural abnormality.
[In Micro-Ophthalmos → Structural Abnormality are present]

↓
angle may get obliterated.

④ PHACOMATOSIS

NF1
Von-Recklinghausen Disease
↓
∠ anomaly

Sturge-Weber Syndrome
TRIAD
- Angioma of face on 1 side
- I/L angioma in Brain
- Angle Glaucoma

## 1° OPEN ANGLE GLAUCOMA.

R/F :-
1) Age > 40yrs
2) +ve Family History
3) High Myopia [>6 D]
4) DM.

Pathogenesis :-
Blockage in TMW

c/E :-




## (I) IOP Changes

* (N) IOP → 10-21 mmHg
* Normal Diurnal Variation ~ 5mmHg
  5-8 mmHg - Suspicious
  >8mmHg - Glaucomatous.

IOP More in Morning as cortisol level are ↑ in morning

* NTG (Normal Tension Glaucoma) -
  Normal IOP
  Fundus changes (+)
  Field Defects (+)

* Ocular HTN -
  IOP ↑
  Fundus (N)
  No Visual Field Defects

IOP varies according to Central Corneal Thickness (CCT)

In thick cornea → overestimate IOP.
In thin " → Underestimate IOP.

# TONOMETRY

- INDENTATION → SCHIOTZ
- APPLANATION
  - Fixed force → area α IOP
    - (1) MAKLAKOV T.
    - (2) BARRAQUER T.
  - Variable force → area is fixed, Force α IOP. [Imbert-Fick law]
    - Most RELIABLE.
    - (1) GOLDMANN
    - (2) PERKINS — For infants
    - (3) DRAEGER
    - (4) TONOPEN — for irregular corneas
    - (5) MAC KAY MARG
    - non-contact: (6) PULSAIR, (7) AIR-PUFF T.
    - for self measurement: (8) REBOUND

Q. C is more Reliable? ⇒ Applanation.
Becoz reading of schiotz depend on scleral rigidity of pt.
In myopia → scleral rigidity is less.

Q. Non-contact Applanation
Air-Puff
Pulsair

Q. For self measurement a? ⇒ Rebound Tonometer

C tonometer used for scarred & irregular cornea
① Tonopen
② Mac Kay Marg

For Infants ① Tonopen
② Perkins

Pascal's Dynamic Contour Tonometer
- It is more reliable than Goldmann
- Becoz reading doesn't depend on CCT.

TONOGRAPHY
measuring facility of aqueous outflow.
used for research purpose.

## (II) FUNDUS CHANGES

① C:D :>0.3
② Difference of C:D b/w 2 eyes >0.2
③ Notching of Neuro-retinal Rim.
④ Thinning of Neuro-retinal Rim
⑤ Laminar Dot Sign
⑥ Changes in Blood vessels.
a) nasal shifting of blood vessels.

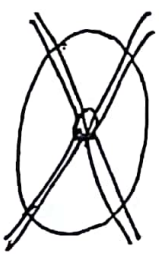

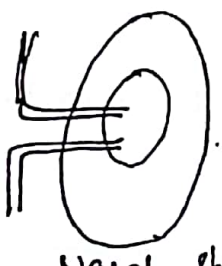

Nasal shifting

b) Bayonetting Sign.
sharp kinking & double bending of blood vessel.

Ideal Method → Slit Lamp Biomicroscopy

↓

Putting lens in front of eye & then looking through slit-lamp.

↓

Contact → Goldmann Three-mirror

Non-Contact → Convex → +60, +78, (+90) Best among this

Non-Contact → Concave → HRUBY LENS −58.6D

## (III) VISUAL FIELD DEFECT

(N) Extent → Temporal 100° or 90°
Inferiorly 70°
Nasally 65°
Superiorly 50°

Blind spot located between 10°-20° in optic

# VFD in 1° OAG

## Early

Earliest VFD

Central or Paracentral Scotoma (in Bjerrum's area)

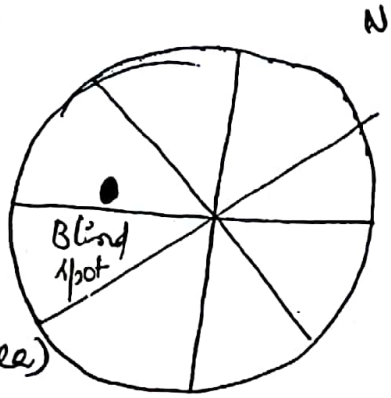


2) Siedel's Scotoma
Paracentral scotoma + Blind spot

3) Baring of Blind spot or Isopter contraction

## Late

④ Arcuate Scotoma

⑤ Double arcuate Scotoma when inf. field is also involved

⑥ ROENNES NASAL STEP

⑦ Central + Temporal Island of vision is left behind.

⑧ Last → Temporal Island of Vision

Baring of Blind Spot :-
- isopter contraction
-

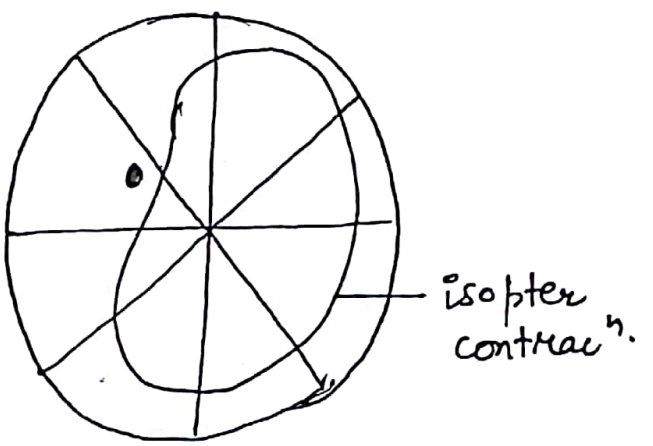

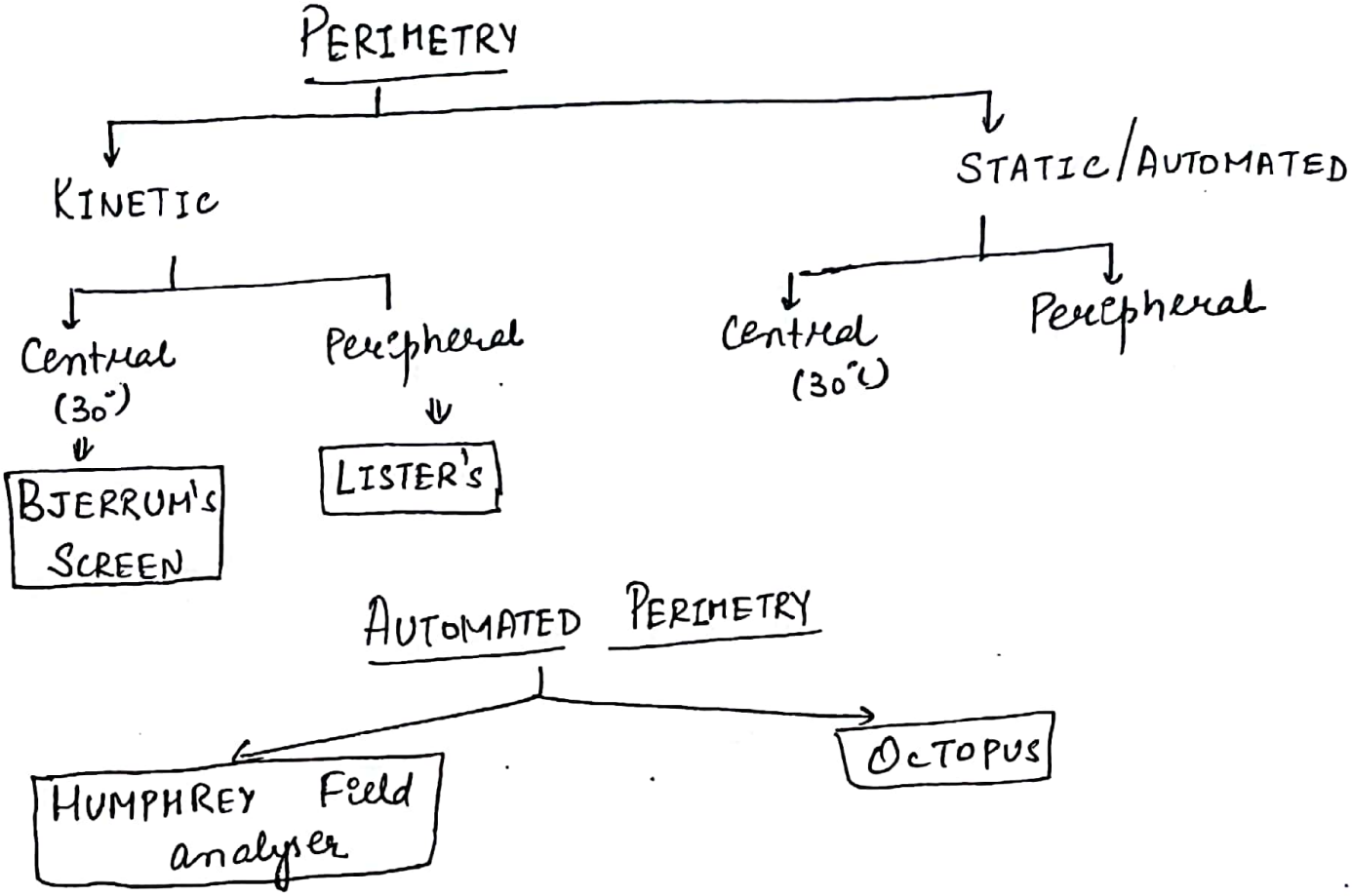


# 1° ANGLE CLOSURE GLAUCOMA

R/F :-

1. Small eye
2. Hypermetropia
3. Shallow AC.
4. Narrow angle
5. MC - ♀

Max. closure of angle occurs ⇒ when pupil is MID-DILATED.

C/F

(I) → PRODROMAL
Asymptomatic

(II) → STAGE OF CONSTANT INSTABILITY
Some part of angle blocks & reopens by itself

(III) → ACUTE CONGESTIVE GLAUCOMA
all 360° angle is closed.
IOP ~ 60 mm Hg
Pain ↑↑, associated c nausea & vomiting
Redness, Photophobia, Blepharospasm.

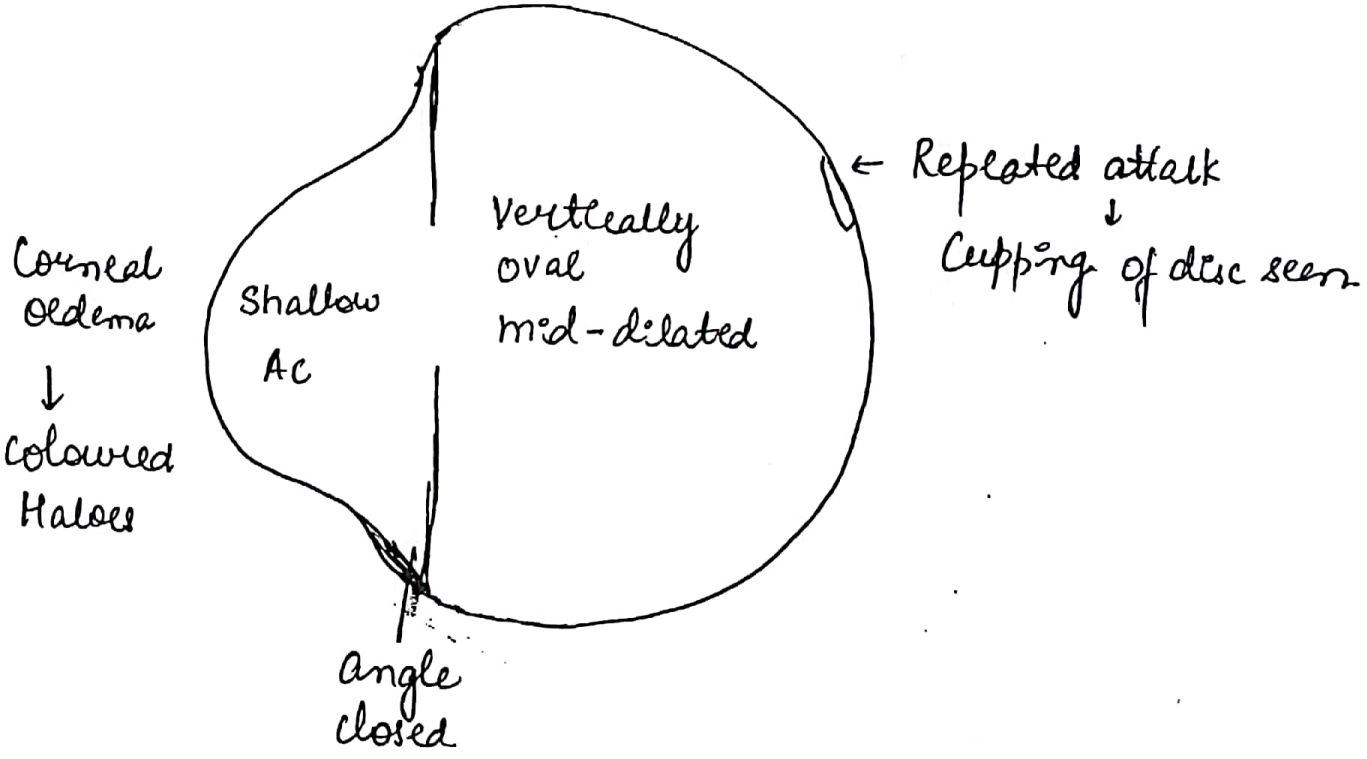


(IV) - CHRONIC CONGESTIVE GLAUCOMA

IOP change
Fundus change
Field defects
+ Angles are closed

For Inv. to see angle ⇒ we need constricted Pupil

(V)- ABSOLUTE GLAUCOMA

Painful Blind Eye.
IOP ↑↑↑
Stony Hard Eyes
100% cupping

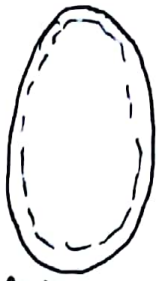

Glaucomatous optic atrophy

TOC of Absolute Glaucoma

- Cyclocryotherapy

↓

Damage few ciliary process

If excessive damage occurs by overtreatment

⇓

PA: PTHISIS BULBI occurs

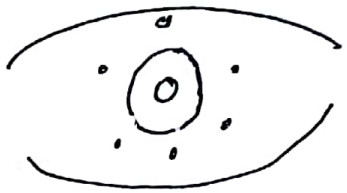

OTHER MODALITIES OF T/t

a) Absolute Alcohol Injection → suppresses ciliary ganglion.

b) Evisceration

Definitive T/t of ACG

Peripheral Iridotomy by NdYAG.

+

Prophylactic PI should be done in other eye.

OAG does not need any prophylactic T/t.

DOC for Angle Closure G/C ⇒ PILOCARPINE.

Doc for Acute Congestive Glaucoma ⇒ MANNITOL or ACETAZOLAMIDE.

followed by pilocarpine

# 2° GLAUCOMA



1) LENS INDUCED GLAUCOMA

a) **Phacolytic Glaucoma**

It is the leakage of lens protein blocking the TMw.
It is seen in Morgagnian Cataract

b) **Phatoxic Glaucoma**

T → T
due to trauma
Any trauma causes capsular rupture
↓
Lens protein blocking TM
⇓
2° OAG.

c) **Phacoanaphylactic Glaucoma**

Lens protein
↓
Immune Reac'
↓
release of macrophages
↓
engulf lens protein
↓
Blocks the TMw.
⇓
2° OAG

Q. ē type of antigen is Lens Protein → **Sequestered antigen**

d) **Phacomorphic Glaucoma**

Due to morphology of lens
When intumescent cataract swells up.
too much ↳
↓
Pupillary Block
⇓
2° ACG

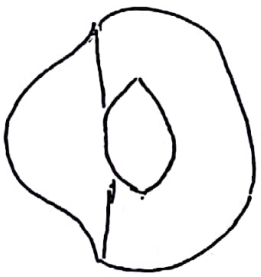

## 2) PIGMENTARY GLAUCOMA

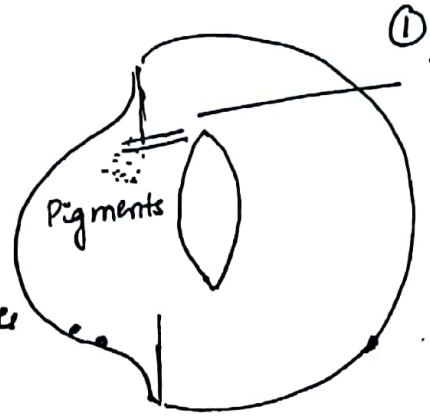


① Transillumination Defect
less pigment hence more light passes through

② Keratic precipitates

Release of pigments
↓
Blocking TM.

KP → spindle shaped
Krukenberg spindles

## 3) PSEUDOEXFOLIATION SYNDROME / GLAUCOMA CAPSULARE

Dandruff like material is released from lens capsule & suspensory ligament
↓
released into aqueous
↓
Blocking TM.

Not true ~~exfoliation~~ exfoliation ⇒ ~~les~~ proteinaceous secretion.

M/c 2° Glaucoma

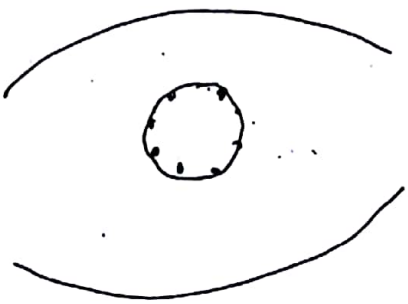

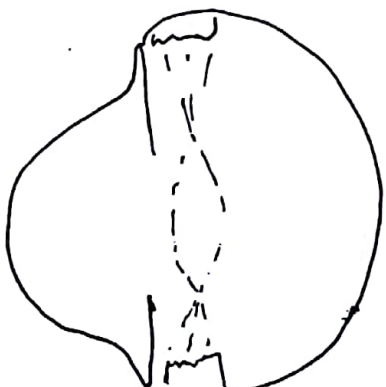

# 4) MALIGNANT GLAUCOMA / CILIARY BLOCK GLAUCOMA

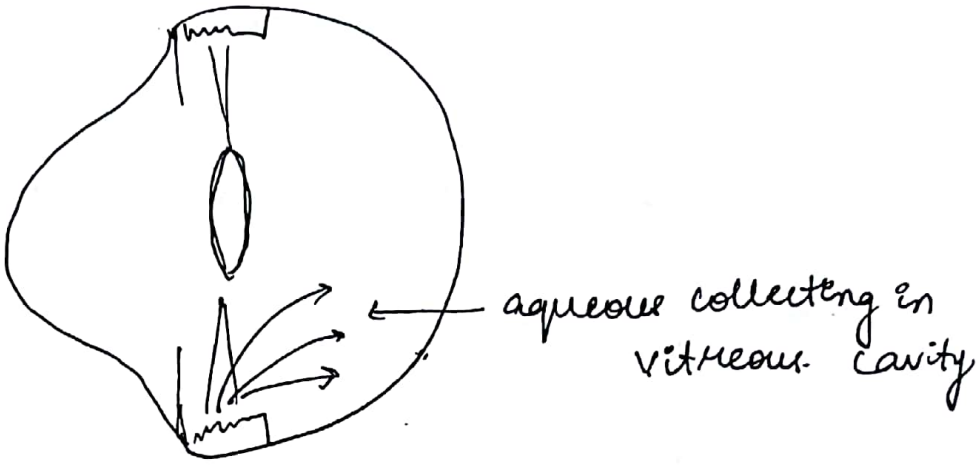


Aqueous formed collects in vitreous Cavity
↓
Lens & Iris pushed forward
↓
very Shallow AC

Cause :- It occurs after any intraocular Sx
c̄ Surgery chances of malignant glaucoma more
Trabeculectomy

Mx

1) Atropine - 1st Line T/t.
Strongest cycloplegic.
Dilatation also opens the block.

2) NdYAG anterior hyaloidotomy
aqueous starts leaking anteriorly
↓
block opens.

3) Pars Plana Vitrectomy
cutting out aqueous from vitreous

Inverse Glaucoma

Glaucomas t/td by Mydriatic

Eg. 1> Malignant Glaucoma

2> Spherophakia

↓

Spherical lens blocks the pupil

↓

a T/td by Mydriatic

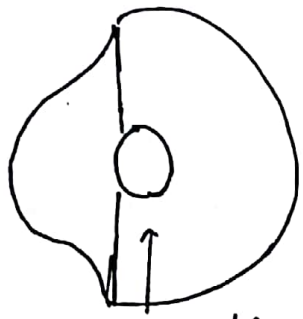

Spherical lens

5> NEOVASCULAR GLAUCOMA

Cause: Hypoxia in retina

↓

neovascularisation.

↓

If hypoxia is not t/td.

Ant segment also hypoxic

↓

Rubeosis Iridis

New blood level are more leaky & have fibrous tissue also.

So, initially it is OAG.

↓

Later associated fibrous tissue contracts.

leading to angle closure

↓

ACG

TOC 1) Pan retinal Photocoagulation.

2) Anti-Glaucoma Drugs

## 6> GLAUCOMA ASSOCIATED WITH UVEITIS

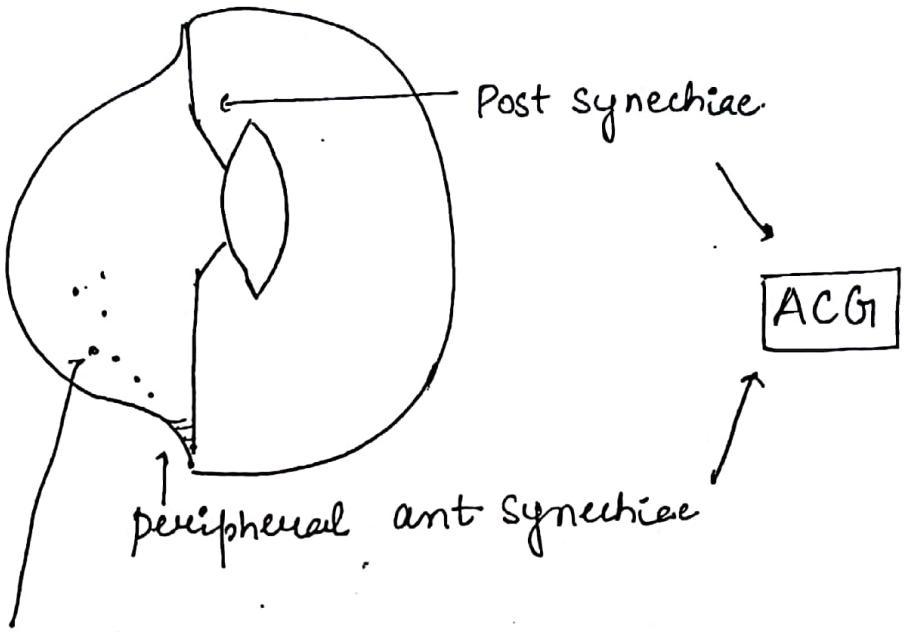


when aqueous cells block TM ⇒ OAG.

Glaucomacyclitic crisis / Hypertensive Uveitis / Posner-Schlossman Syndrome.

In uveitis, pupil is miotic ; ACG pupil → mid-dilated or Dilated.

↑ This helps in diagnosis of this syndrome

TOC

1) Anti-Glaucoma Drugs

2) Atropine.
for uveitis

when pressure is controlled ⇒ go c steroids.

## 7) STEROID INDUCED GLAUCOMA

M/c ocular complication of topical steroids.

Deposition of Mucopolysaccharides in TMW.

⇓

OAG.

## 8) ICE Syndrome [Irido-corneo-endothelial Syndrome]

Endothelial never regenerates (N)

In this syndrome,

endothelium starts proliferating

↓

Block's angle

**Proliferative endotheliopathy + 2° Glaucoma**

- Progressive Iris atrophy → Iris atrophy
- CHANDLERS SYNDROME → Corneal oedema
- COGAN REESE SYNDROME → Nodules + Naeves on Iris

# Rx OF GLAUCOMA

- Medical
  - Topical
  - Systemic
- Laser
- Sx

## TOPICAL DRUGS

1) β BLOCKER

MOA - ↓ formation

Eg - TIMOLOL
BETAXOLOL
LEVOBUNALOL

Q. c/I in β blocker = asthma

Selective β blocker = Betaxolol

c/I β block called ● NLD obstruction = Timolol

2) α - AGONIST

MOA - Dual action

- ↓ formation
- ↑ drainage [Uveoscleral outflow] Preferred

Eg - EPINEPHRINE / ADRENALINE
DIPIVEFRINE
BRIMONIDINE
APRACLONIDINE

α agonist C/I – HTN
Heart Disease

Selective α agonist - Brimonidine
Apraclonidine

c anti glaucoma Drug causes drowsiness = Brimonidine

c " • C/I in Infants = Brimonidine
↓
can cause CNS depression

conjunctival pigmentation → by adrenaline

3) MIOTICS

MOA -1) ↑ conventional outflow [trabecular] Q.

2) Miosis in ACG opens up angle.

Eg Pilocarpine ↓ uveoscleral outflow.
↳ C/I in pts of uveitis bcoz miosis aggravates inflammation

miosis

↑ capillary permeability

4) PROSTAGLANDIN ANALOGUE [PG $F2_\alpha$ agonist]

MOA - ↑ uveoscleral outflow.

Eg - LATANOPROST
BIMATOPROST
TRAVOPROST

c Drug causes Heterochromic Iridis - Latanoprost
↓
Becoz it causes IRIS Pigmentation

C Antiglaucoma drug ↑ (B) outflows = Bimatoprost.

C/I in uveitis as they are mediators of inflammation.

5) CARBONIC ANHYDRASE INHIBITOR

MoA - ↓ formation of aqueous humour

Topical CA inhibitors = DORZOLAMIDE
BRINZOLAMIDE

c/I in sulpha allergies

## SYSTEMIC DRUGS

CARBONIC ANHYDRASE INHIBITOR

c/I in sulpha allergies

HYPEROSMOTIC AGENTS

MANNITOL
GLYCEROL
ISOSORBIDE
UREA.

# LASER

- OAG
  - Trabeculoplasty by photocoagulative Laser.
    - ↓
    - apply Lasee on pigmented TMW
- ACG
  - Peripheral Iridotomy by Nd YAG

## Sx

1> GONIOTOMY

Cut in TMW ⇒ TOC of Congenital Glaucoma

2> TRABECULOTOMY

Cong. Glaucoma
When cornea is not clear.
Cut in TMW + Schlemm's Canal.
It is also done along ~ Trabeculectomy.

3> TRABECULECTOMY

Cutting TM
↓
Direct connec"

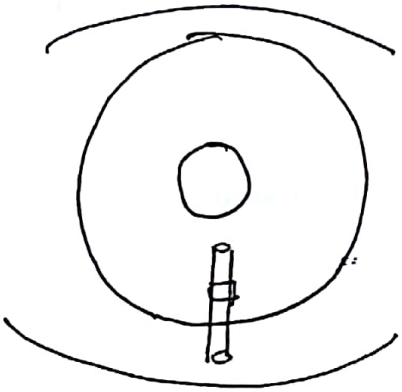

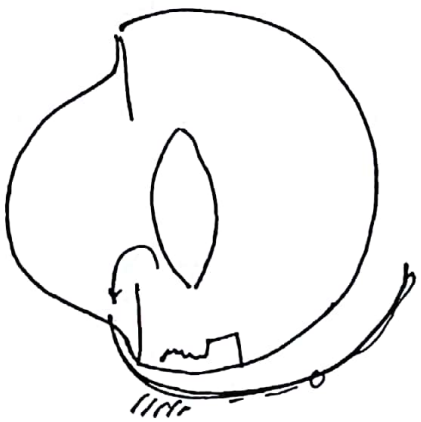

Resection of TM
↓
making a fistula bet$^{n}$ AC & Subconjunctival space
↓
Direct connection.

Steps :-
Constricted Pupil
↓
Cut Conjunctiva & make a flap.
↓
resect tenon's capsule
↓
on sclera. → V shaped partial cut
↓
directing
↓
on limbus. cut a block of TM
↓
Do iridectomy
↓
Put flap. & loosely
Suture it.
↳ so that aqueous flow.

BLEB - Conjunctival flap is raised due to aqueous flow underneath.
Once of bleb indicates success of process.



## PRECAUTION for closure of fistula

- Anti-Mitotic Drugs
  - Mitomycin C
  - 5FU
- ~~5FU~~

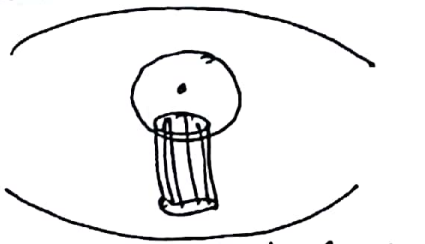

aqueous drainage implant

## Aqueous Drainage Implants

1> MOLTENO IMPLANT (older)

It causes hypotony. [Iop < 10mmHg]
made up of ~~two~~ polypropylene

2> AGV (Ahmed Glaucoma valve)
made up of silicon.

3) EXPRES IMPLANT
made up of stainless steel.

# CORNEA

## STRUCTURE OF CORNEA

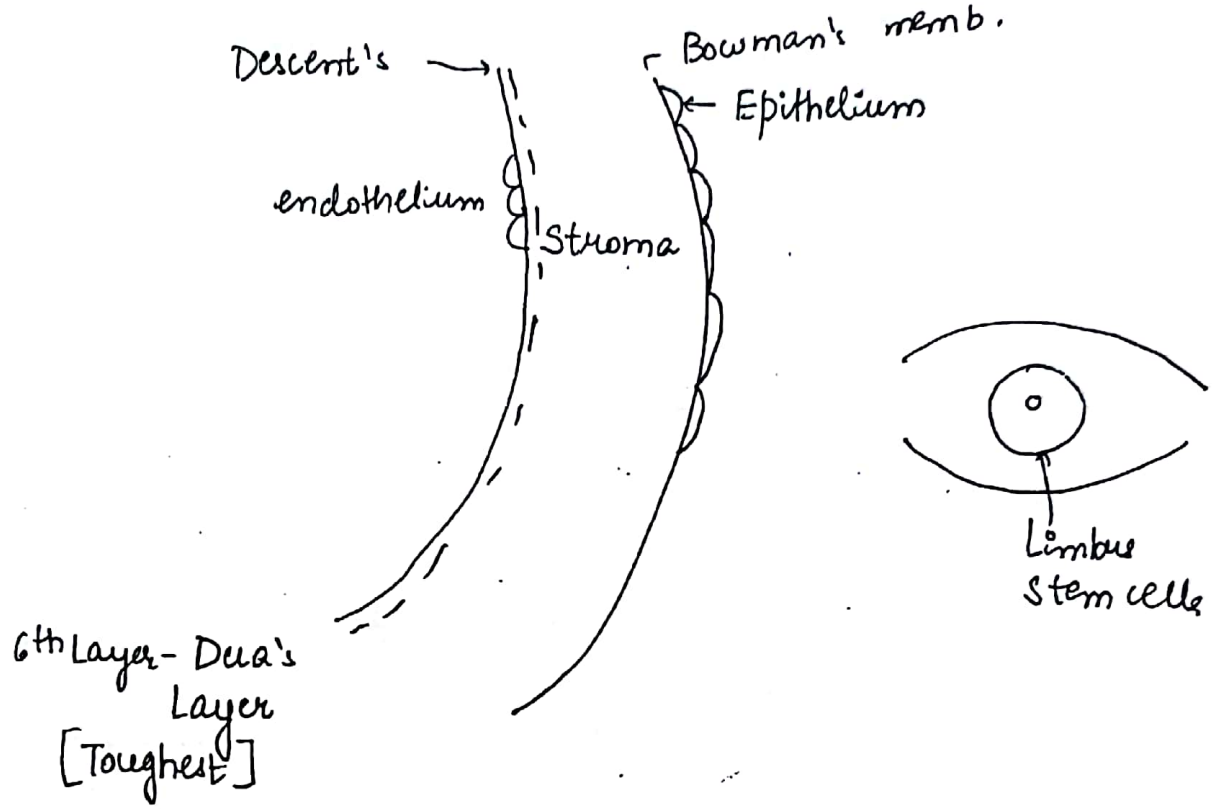


Epithelium grows from Limbus stemcells

### PHYSIOLOGY

1> Avascular

2> 1° metabolism ⇒ AEROBIC

- $O_2$ from air
- Nutrition from aqueous humour

3) Dehydrated

↳ endothelium act as barrier

↳ Pump function :- $Na^+$ $K^+$ ATPase pump

↳ continuously pumps out water.

(N) No. Of endothelial cells.
adults - 2500 - 3000 cells/$mm^2$.
children - 3500 - 5500 cells/$mm^2$.

Polymegathism
whenever endothelial cells damage compensatory change occurs in size ⇒ Size enlarges

Pleomorphism
Morphological change in shape when endothelial cells get damaged.

When Total No. of cells. <500 cells/$mm^2$ ⇒ Further No compensation.

⇓

Pump function ↓

⇓

Hydration.

↓

initially Stromal oedema

later epithelial "

↓

Bully filled ± fluid

⇓

BULLOUS KERATOPATHY

It is a sign of corneal decompensation.

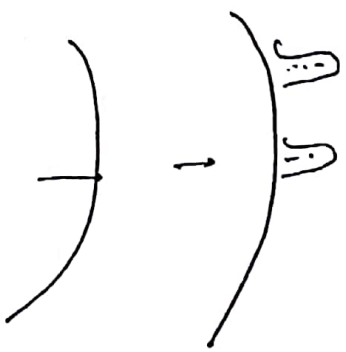

Metabolically Most Active Layer = ENDOTHELIUM

∴ Layer in involved in Bullous Keratopathy = EPITHELIUM.

∴ are layers of cornea & do not regenerate

1) ENDOTHELIUM
2) BOWMAN'S MEMBRANE

## FACTORS RESPONSIBLE TO MAINTAIN TRANSPARENCY

1) Regular arrangement of epithelium
2) " " of stromal lamella

Distance Bet" 2 lamelle $< \frac{1}{2}$ ($\lambda$ of light).

3) Dehydration
   - Pump func"
   - Barrier "

   } of endothelium.

4) Avascularity

## ULCER

Breech in the continuity of epithelium.



ORGANISMS ∴ PENETRATE INTACT EPITHELIUM.

NNLDH

N - Neisseria Gonorrhoea
N - " Meningitis.
L - Listeria
D - Diphtheria
H - Haemophilus

# INV. RELATED TO CORNEA

① Keratometry — measure curvature of cornea
Scanning central part

② Corneal Topography
Curvature of cornea measurment
Scan whole cornea

③ Phacymetry
thickness measurment
(N) 0.5-0.6 mm (centre)
at Limbus - 1 mm.

④ Specularmicroscopy ?
Examine endothelial cells [Both No. & Morphology]

⑤ Corneal Sensation
ASTHESIOMETER - hair like projection touches corneal surface.

⑥ Microbiological
- staining
- culture

# KERATITIS

Inflammation of Cornea.

- Pain
- Redness
- Photophobia
- Blepharospasm
- D/c

## REDNESS

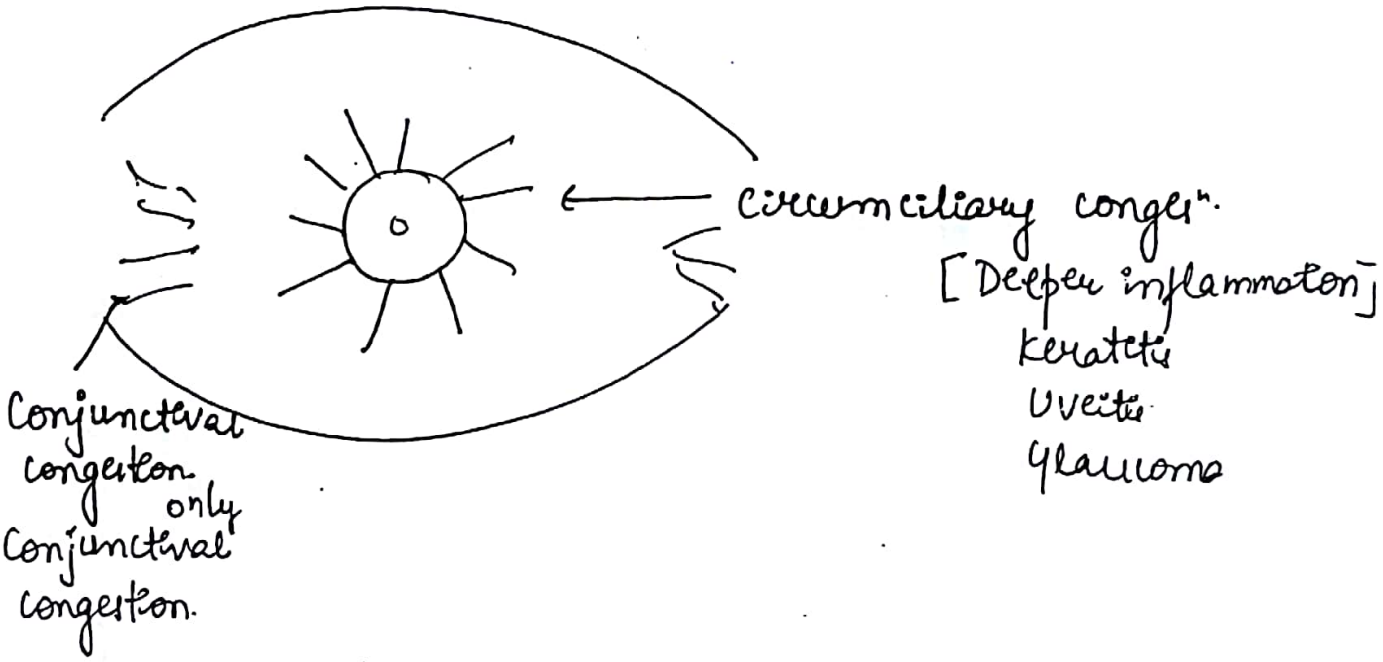


## BACTERIAL KERATITIS

Presents ī (5) above features

O/E → Flourescene stained +ve ulcer

Pus in AC [Hypopyon] → Sterile

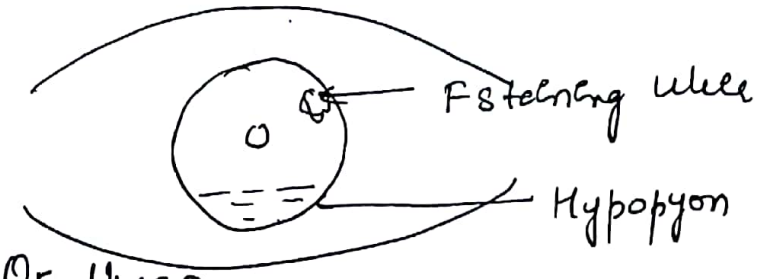


## FATE OF ULCER

- **Localised**
  - ↓ T/t - heals c̄ opacity
- **Perforating**
  - ↓ causes corneal thining leading to perforation
  - ↓ when iris gets adhered & seals perforation [Leucoma adherence]
- **Sloughing**
  - ↓ virulent organism
  - ↓ Necrosis
  - ↓ Replaced by inflammatory exudates [Pseudocornea]

**Hypopyon Corneal Ulcer** :- PNEUMOCOCCUS
or
**ULCUS SERPENS**

Rx

1) Antibiotics
   - Broad spectrum
   - culture sensitivity

2) Fortified antibiotics drops
   - CEFAZOLINE → 50 mg/mL
   - GENTAMYCINE → 15 mg/mL

3) Antibiotic Ointment applied - HS

4) Atropine.
   Since Keratitis may cause uveitis.

5) Oral Anti-inflammatory

6) Oral Vit A / Vit C

For any infective corneal ulcer ⇒ No steroids
No Bandage
↓
Flaring

## Rx of NON-HEALING ULCER

1) **Debridement**
Remove necrotic tissue from periphery using sterilized cotton bud

2) **Chemical Cauterisation**
TCA (trichloroacetic acid)
↓
local antiseptic effect

3) **Conjunctival flapping**
raise a flap of conjunctiva + cover the ulcer
Gundersan's Conjunctival flapping

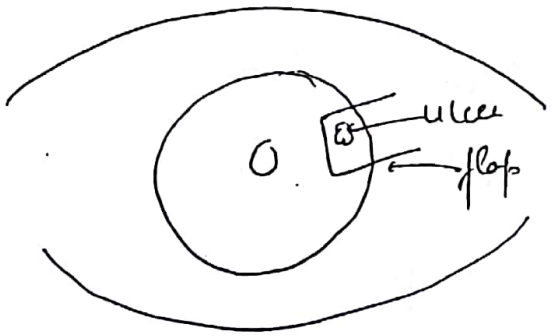


## Rx of IMPENDING PERFORATION

1) Anti-Glaucoma Drugs.
↓ IOP

2) Cyanoacrylate Glue application on thin area.

③ Bandage contact Lens
Soft lens
High water content
More $H_2O$ → More $O_2$ transfer ability

CONTACT LENS
Soft ← → Semi-Soft
↓
Rigid Gas Permeable

## FUNGAL KERATITIS / KERATOMYCOSIS [AIIMS]

CAUSE - Trauma by Vegetative matter
common in farmers
Signs are more than symptoms compared to bacteria

M/C Fungus ⇒ ① ASPERGILLUS FUMIGATUS Q
↓
② FUSARIUM. Q.

M/C Fungus infecting eyes → Candida albicans

C/F:- 5 features

O/E → 1) Ulcer is dry & rough.
2) Projecting ends → HYPHAE

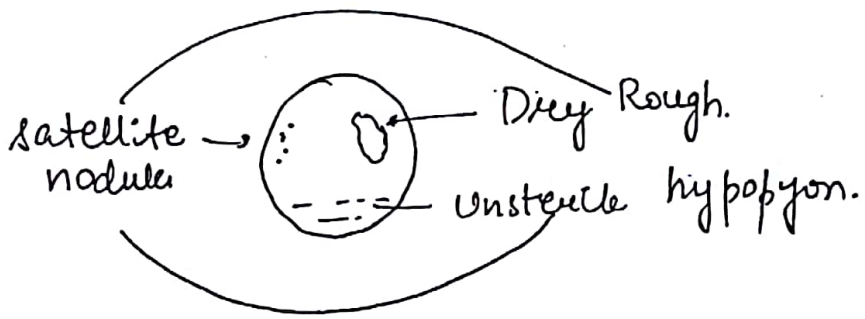


3) Unsterile Hypopyon.
4) Satellite nodules Q

Inv -

Staining
1) KOH Smear
2) Gommori's Methamine Silver Stain.

Culture
- Saboraud's Agar
- Brain Heart Infusion Broth.

Keratitis caused by NOCARDIA ASTEROIDES, ☾ is a filamentous bacteria closely resembles FUNGAL CORNEAL ULCER ☾☾

℞
DOC → NATAMYCIN

Others - Nystatin eye ointment
Fluconazole → Most effective against Candida

# VIRAL KERATITIS

☾ is more common = Herpes Simplex M/c than Herpes Zoster. Ophthalmicus

Pathognomic feature
↓ corneal sensation.

**CAUSES OF ↓ CORNEAL SENSATION**

1) Leprosy
2) DM
3) Absolute Glaucoma
4) Phthisis Bulbi
5) any chr. degenerative disease of cornea
6) Section of trigeminal n/v
7) Viral keratitis

# HERPES SIMPLEX KERATITIS



O/E :-

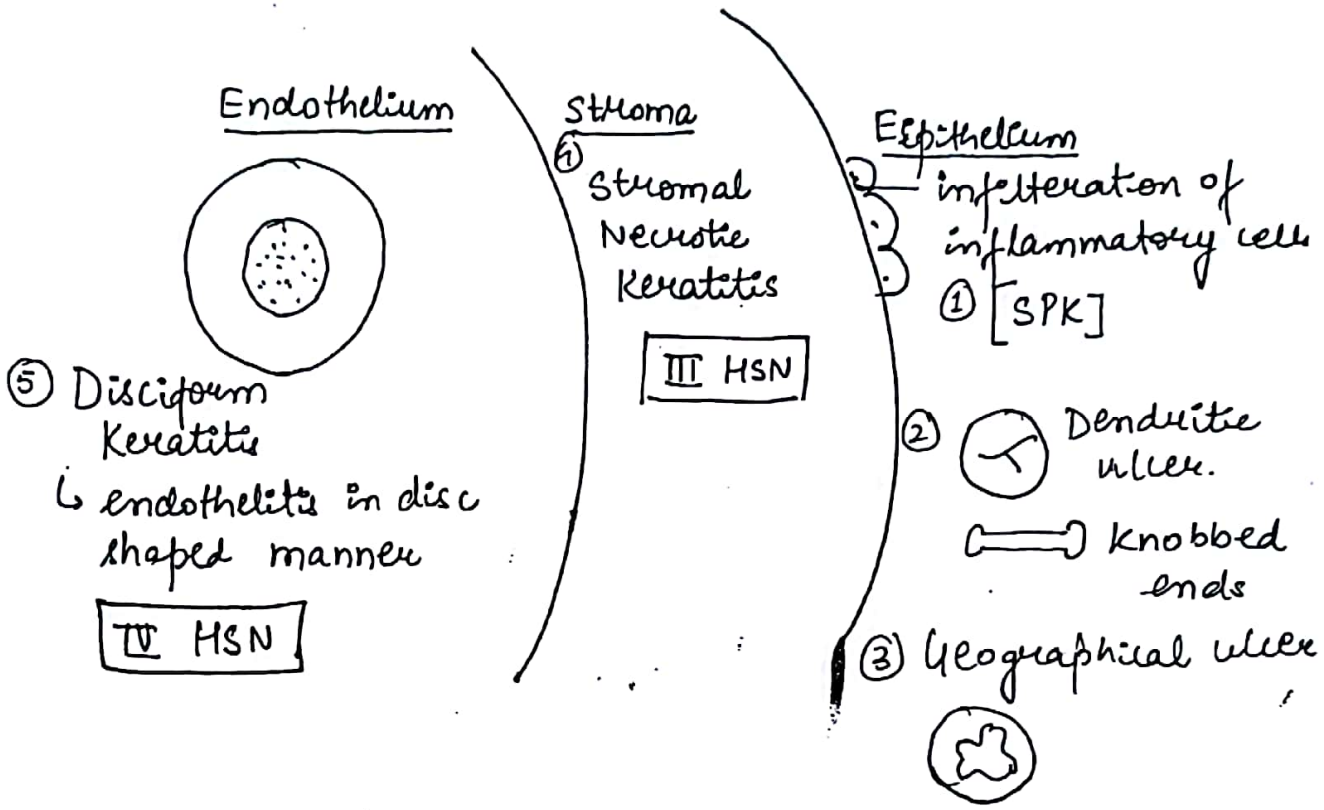


Stromal Necrotic keratitis & Disciform keratitis may be a manifestation of HSN Reac$^{n}$.

℞ :-

1% Acyclovir Eye Ointment - 5 times/day. [

acyclovir drops not available

- Ideal duration - not exceeding 14 days.

# HERPES ZOSTER OPHTHALMICUS

Skin ← | ↓ Eye | → Trigeminal neuralgia

**Hutchison's Rule** :-

If tip of nose is involved, eye will be involved.

Indicates involvement of Nasociliary N/V

C/F :- ⑤ same severe inflammation.

O/E :-

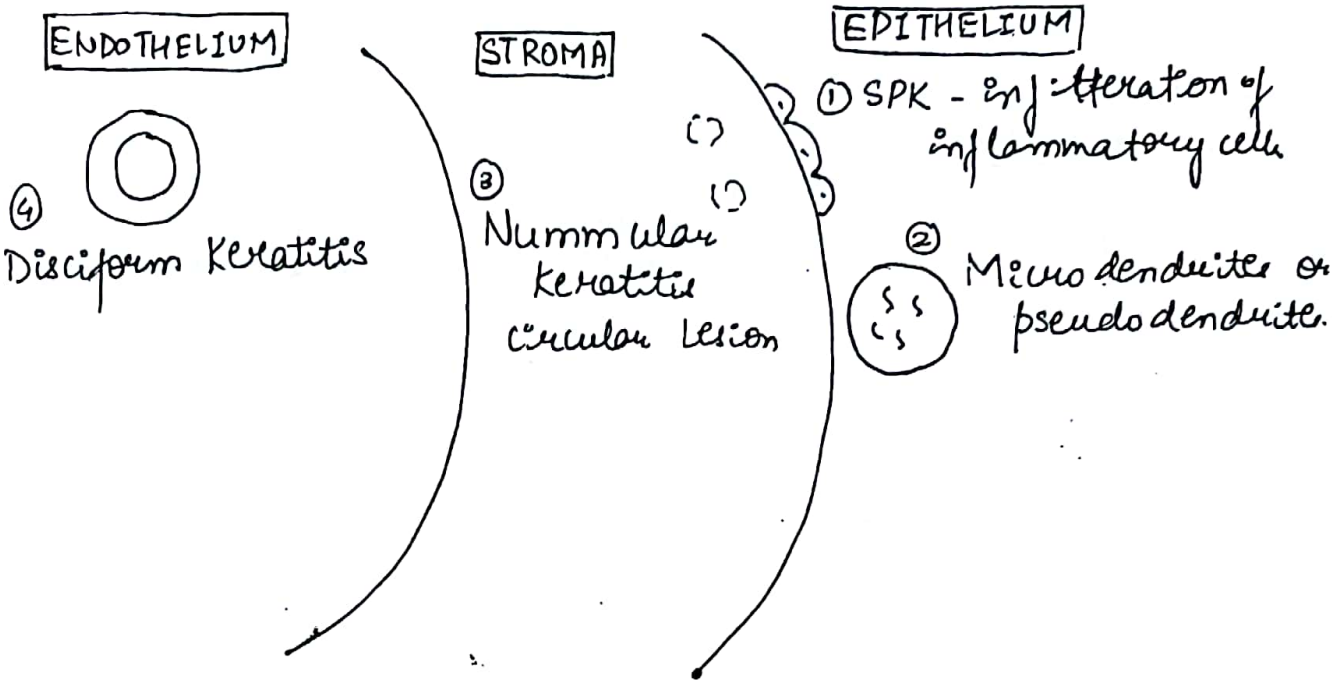


⑤ Uveitis

⑥ Cranial n/v Palsies

③ 4, 6
M/c

M/c N/V involved in zoster = FRONTAL N/V

Rx :-

1) Topical is same
3% Acyclovir eye ointment - 5 times/day

2) Oral Acyclovir (800mg) tab - 5 times/day ] till 14 days.

3) Valcyclovir (1000mg) tab 3 times/day. ]

Metaherpetic keratitis -
Over t/t ☹ antivirals.
Toxicity → T/t — ① Stop antivirals
② start Lubricating eye drops

# ACANTHAMOEBA KERATITIS

Rare infection

cause:- 1) users washing soft contact lens ~~c~~ tap water

2) swimming ~~c~~ out goggles in soft contact lens user

C/F- (5) same

Pain is disproportionately much more

↳ due to perineural invasion.

O/E -

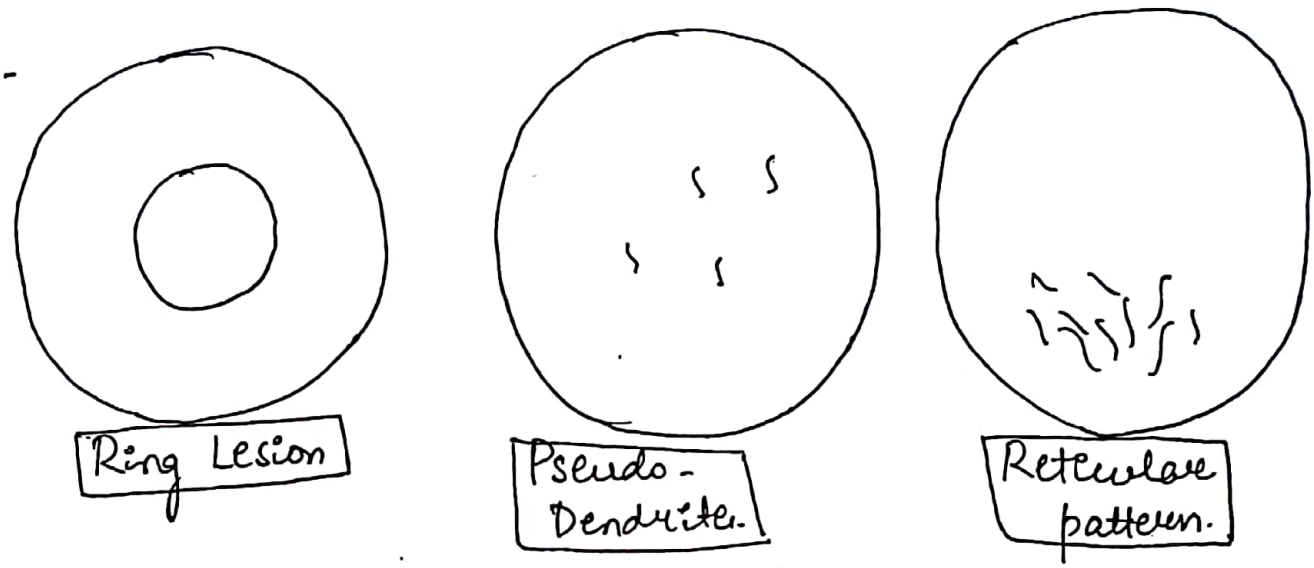


Inv :-

Staining

1) Calcoflour white
2) Acridine orange
3) Lactophenol Blue.

Culture

Q. Op Non-nutrient agar ~~c~~ E.Coli

Rx :-

1) PHMB [Poly Hexa Methylene Biguanides]
2) Propamidine isethionate
3) Neomycin.

DOC → PHMB

# INTERSTITIAL KERATITIS

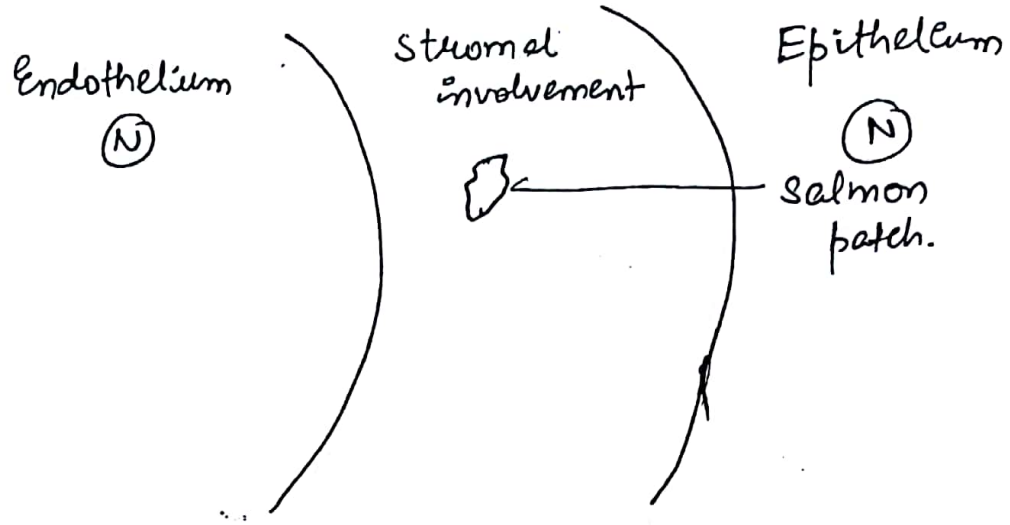


IK Syp Le TB Ca Sar.

Causes :- 1) Syphilis
2) Lepresy
3) TB
4) Sarcoidosis
5) COGAN SYNDROME → **IK + Deafness**

Other causes- 1) acanthamoeba
2) Herpes simplex
3) Herpes zoster

Not a feature of Chlamydia

SALMON PATCH → is a feature of **Syphilis**

# KERATOCONUS

- Ectatic Dystrophy of Cornea characterised by conical protrusion.

~~No~~ Dystrophy is idiopathic spontaneous change ∴ no inflammatory component

- Genetic Disease : AD
- Slowly Progressive



If whole cornea is protruded out = Keratoglobus → Myopia.

In Keratoconus → Myopia + Irregular Astigmatism.

↓

Pt complains of Diminution of Vision.

O/E :-

1) Fleischer's Ring
   Fe Deposition in Epithelium

2) MUNSEN'S SIGN
   V shaped deformity of lower lid on downgaze

3) CORNEAL TOPOGRAPHY
   → irregular astigmatism.

4) RETINOSCOPY
   → scissor's reflex. Q.

5) Prominent corneal n/v
   ↳ it is due to thinning of cornea

6) Vogt's Striae
   Break in Descemet's membrane
   in keratonus → parallel to steeper axis.

**Thickening of Corneal N/v**
1) Leprosy
2) NF-1
3) ~~1~~

Q How to differentiate bet" Haab's & Vogt's Striae?

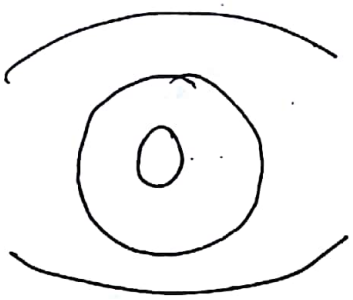

Haab's - circular

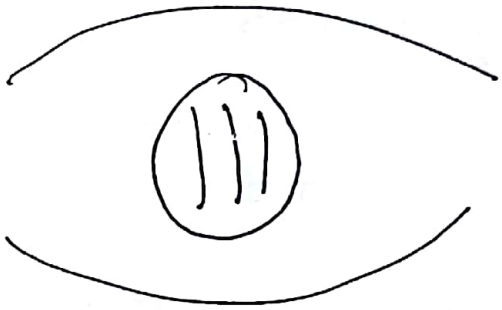

Vogt's = Vertical

Rx:-
1) Spects
in early stage effective

2) Contact lens
Rigid Gas Permeable lens

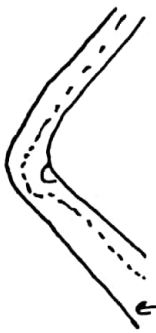

← rigid gas permeable

③ $C_3R$
Corneal collagen cross-linking
ī Riboflavin

expose ~~the~~ it to UV-A rays for 30 minutes.
↳ it arrests progression of disease

4) ~~Ke~~ Penetrating Keratoplasty (PK)

# Keratoplasty

- Corneal Transplantation (Donor)
- Replacement of Diseased cornea by normal cornea
- Donor cornea from Cadeveric Eyes
  c in 6hrs death.
  may extend to 12 hrs.
- Storage Media

Short-term
for 48 hrs
in Moist chamber

Intermediate storage
for 4 days
MK [McCarey Kaufmann media].

Long-Term storage
30 day organ culture
Indefinite time period
Cryopreservation

## Types

PENETRATING
(full thickness)

LAMELLAR LK
(partial thickness)

DALK [Deep ant.]
epi
sb
Endo

DELK [Deep endothelial]
or DSEK

DSEK - Descemet Stripping endothelial Keratoplasty

↓

% of endothelial cell loss - 20-25%

* Min. endothelial cells in corneal graft
= 1500 cells / $mm^2$

# CORNEAL DEGENERATIONS

Age Related

## ARCUS SENILIS

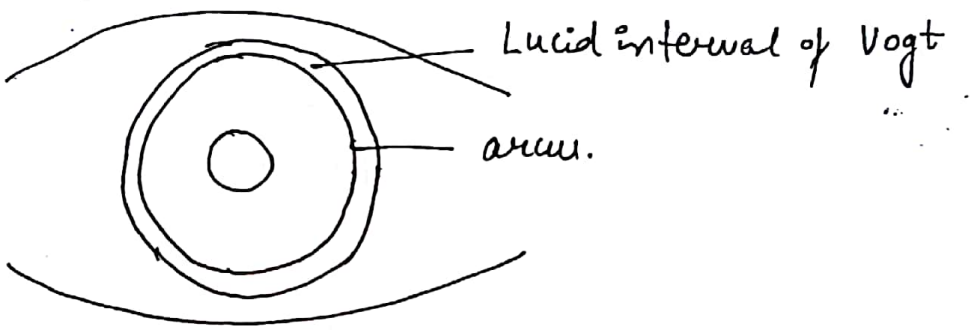


cause :- Lipid Deposition.

↳ in **Stromal Layer**

## BAND SHAPED KERATOPATHY

It is deposition of calcium in form of a band.
Subepithelial Deposition.

CAUSE

1) Idiopathic - H/c
2) Chr. Uveitis in children suffering from JRA (Juvenile Rheumatoid arthritis)
3) Phthisis Bulbi
4) Hypercalcemia → also seen in Sarcoidosis

Rx -

1) Chelation ī EDTA

# CORNEAL OPACITIES

Scar formed when stroma is involved

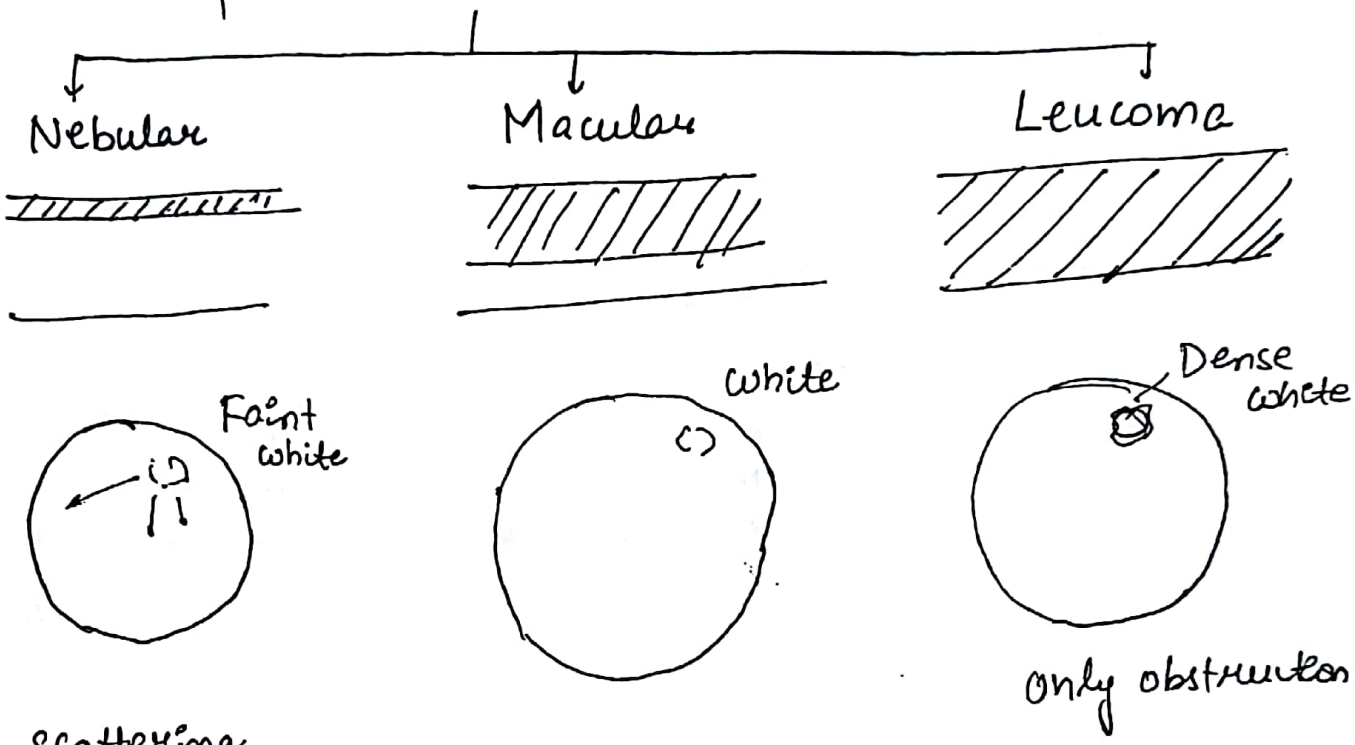


Scattering
Defraction
↓
interfere ī func" of clear cornea.

**Diminishes vision most**

Pannus = Neovascularization on cornea.
from Limbal capillaries

# CORNEAL DYSTROPHY

- Epithelial
- Stromal
- Endothelium.

## 1) EPITHELIAL DYSTROPHY-

Pt. presents ⊂ recurrent ~~corneal~~ epithelial erosions

$R_x$ - ① Pad/Bandage ⊂ antibiotic ointment

② Keratoplasty

TYPES

- Micro-cystic / Finger Print / Map Dot
  - ↳ M/c type. overall
- Meesmans Dystrophy.
- Reis-Bucklers
  - Main pathology in Bowmans Membrane

## 2) STROMAL DYSTROPHY -

Present ⊂ Diminition of Vision

$R_x$ - Keratoplasty

TYPES

- Macular
  - ↳ overall
  - ① Least common
  - ② AR inheritance
  - ③ a/w Mucopolysaccharidosis
- Granular
- Lattice
  - a/w amyloidosis
  - Lattice Type II
  - M/c Stromal type

## 3) ENDOTHELIAL DYSTROPHY

C/F - Corneal oedema

T/t → ① Hypertonic saline eye drops

② Keratoplasty

Fuch's endothelial Dystrophy

Posterior Polymorphous dystrophy.

Corneal Guttatae.
Collagenous protuberances if present on central cornea

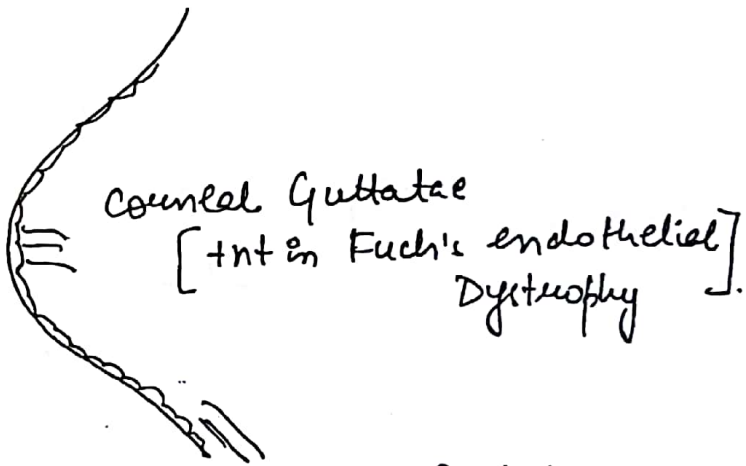

# SCLERA

## SCLERITIS

1) Granulomatous Inflammation of Scleral Coat
2) Development
   1) Neural crest
   2) Temporal part - mesoderm
3) Thinnest part of sclera
   post to m/s insertion.

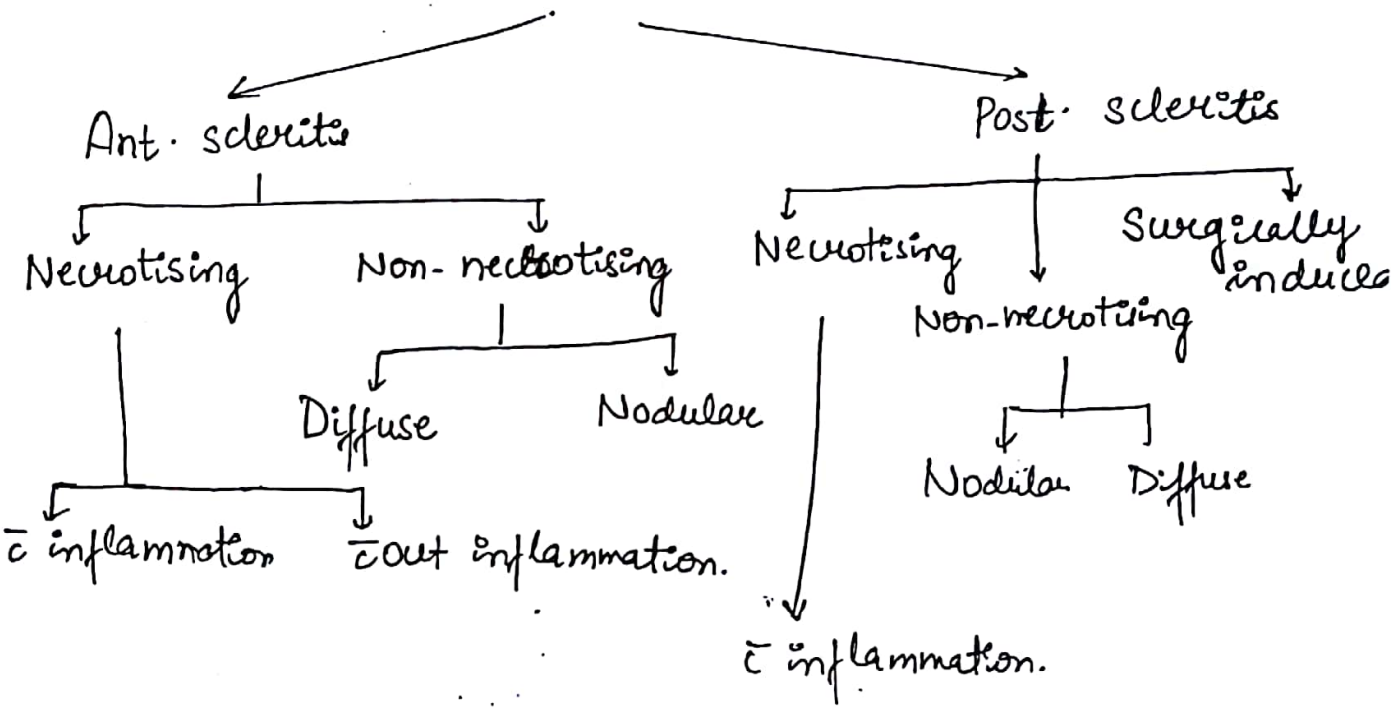


They are associated c connective tissue Disorder

1) RA
2) Polyarteritis nodosa
3) SLE.

Rx - 1) NSAID
   Topical.

2) Steroids

③ Immunosuppressive Drugs in necrotising sclerosis.

## SCLEROMALACIA PERFORANS

- Necrotising Ant. Scleritis c̄ out inflammation
- Seen in pts of long standing Sero +ve RA.

C/F → yellow necrotic patch on sclera
↓
Later marked thinning of sclera
↓
exposed uveal tissue

Perforation is rare.

## STAPHYLOMA

Ectatic Cond$^n$ of Eyeball c̄ herniation of uveal tissue.

### TYPES

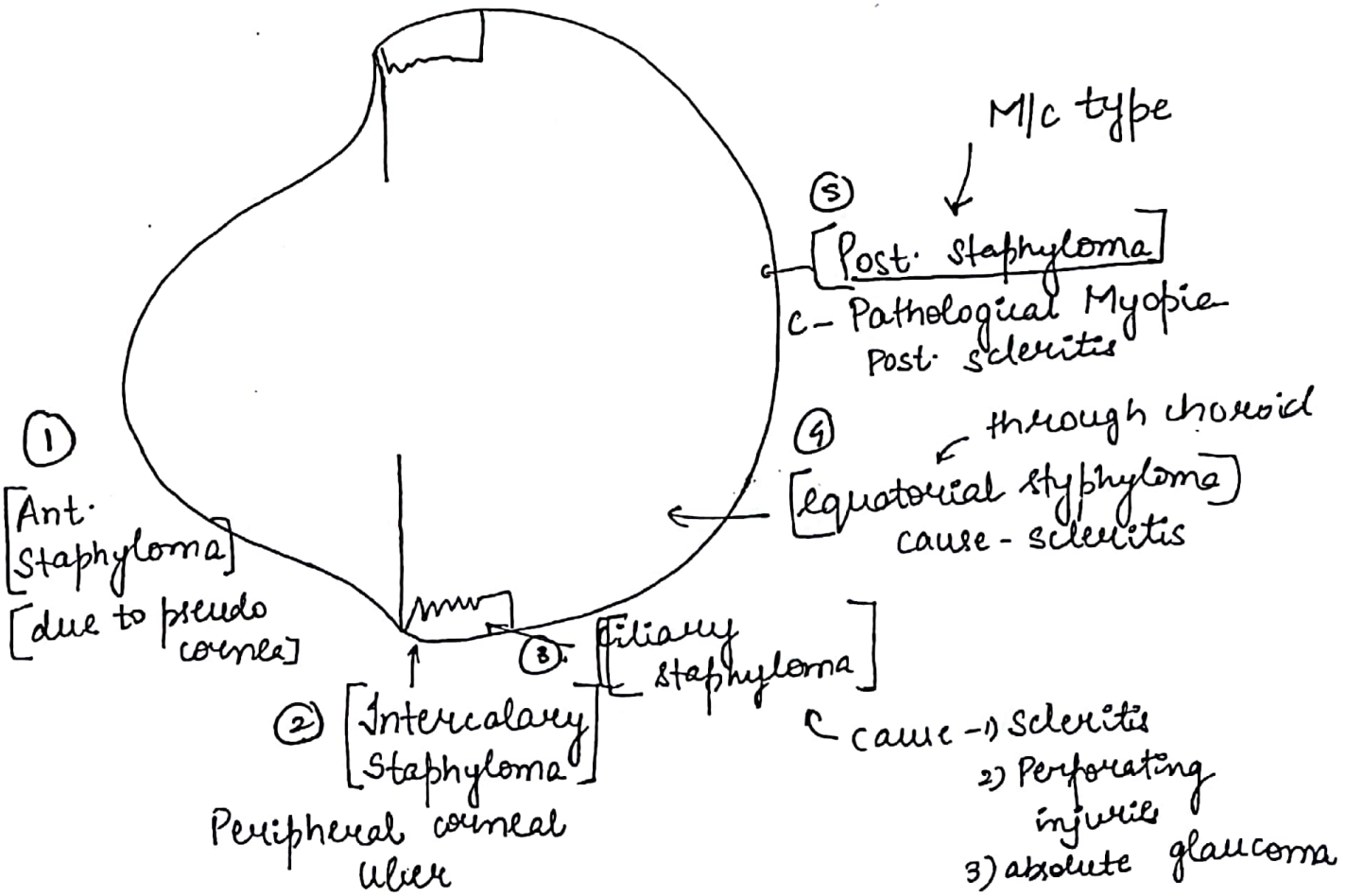

# UVEITIS

Inflammation of uveal tissue

CLASSIFICATION

- ANATOMICALLY
  - Ant. Uveitis — Iris + Pars plicata [Iridocyclitis]
  - Intermediate uveitis — Pars Plana [Pars planitis]
  - Post uveitis — Choroiditis
- PATHOLOPICALLY
  - Granulomatous → Nodule formation.
  - Non-granulomatous

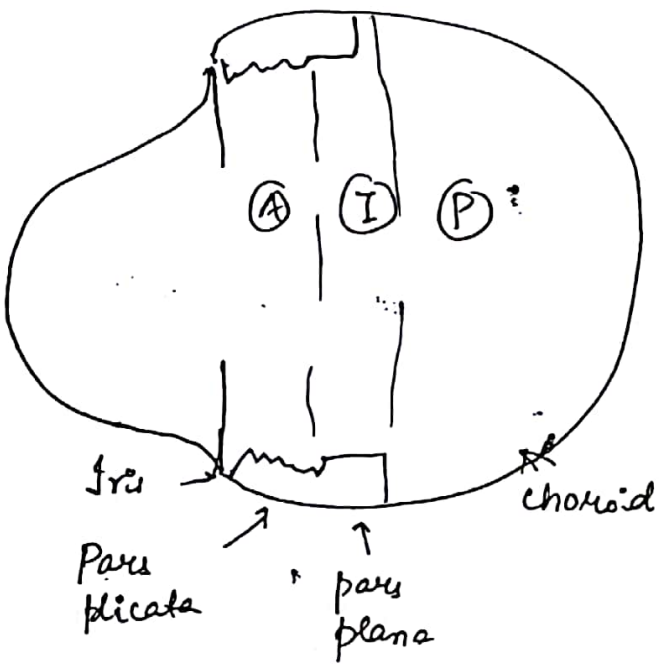


Weakest part of Iris → ROOT → where it is attached to ciliary body

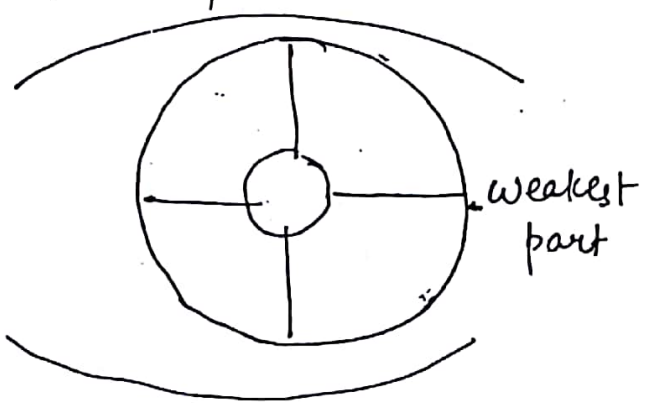

Any disinsertion is called **Iridodialysis**

↓

D shaped Pupil

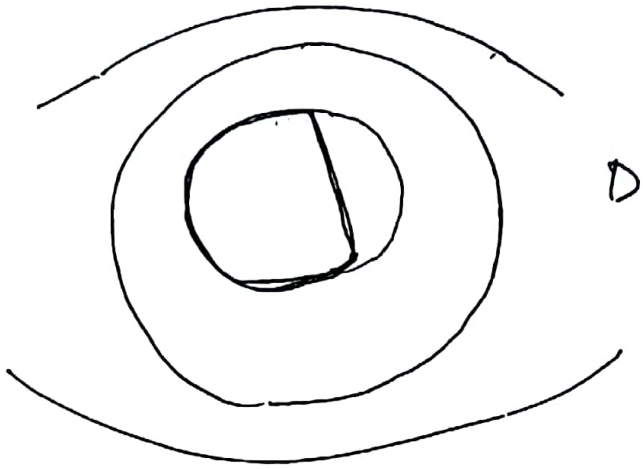

D shaped Pupil.

# ANTERIOR UVEITIS

C/F

(5) - Those (5) features.

Redness - ciliary

D/c - watery / serous

O/E

(5) Busaca nodules (at Base)

(2) Aqueous flare [due to protein leakage]

(1) Aqueous cells

[Toxins from inflammed tissue]

(4) Miosis

(3) Muddy Iris [oedematous]

(6) Koepp's nodules (at pupillary margin)

Hallmark feature of Ant. Uveitis ⇒ KP'

| Non-Granulomatous | Granulomatous |
|---|---|
| Fine, | Large, Greasy [MUTTON FAT] |

KP's are seen on lower cornea due to convec° current in aqueous humour.

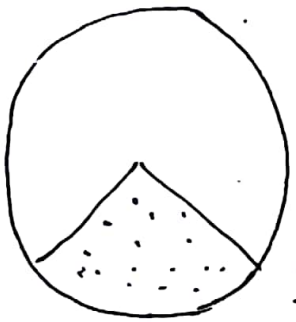

ARLT'S Δ

Pathogenesis

Inflammation causes ↑ capillary permeability
↓
Leads to leakage of cell + protein.

(7) Feestoned shaped pupil.
post. Synechiae
on dilatation, this appearence



(8) Seclusio Pupillae / Ring Synechia
Aq. humour starts collecting in Pc.
Synechia forms.

⑧ Iris Bombe

Aqueous humour push iris forward

↓

causes angle block later on.

↓

ACG.

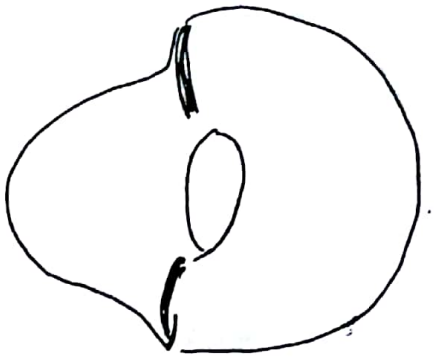

Fibrous tissue forms all over pupil

⑨ ↳ occlusio Pupillae →

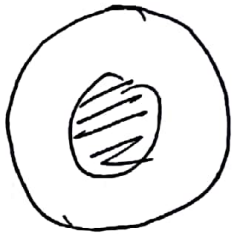

Cyclitic Membrane

Inflammatory membrane formed behind Iris

℞

1) TOC of Ant. Uveitis → Topical Steroids.

2) Topical Cycloplegics.

Adv

a) ~~release~~ relieves spasm give rest to ciliary m/s ↳ Better vasculature

b) relieves pain

c) prevents post synechiae.

d) Breaks the post. synechiae

LUMINATE Programme –

Study to find non-steroidal t/t of Uveitis.

Drugs being studified – Voclosporin

# INTERMEDIATE UVEITIS



1) young ♂
2) C/F - Blurring of vision (U/L)
3) O/E -

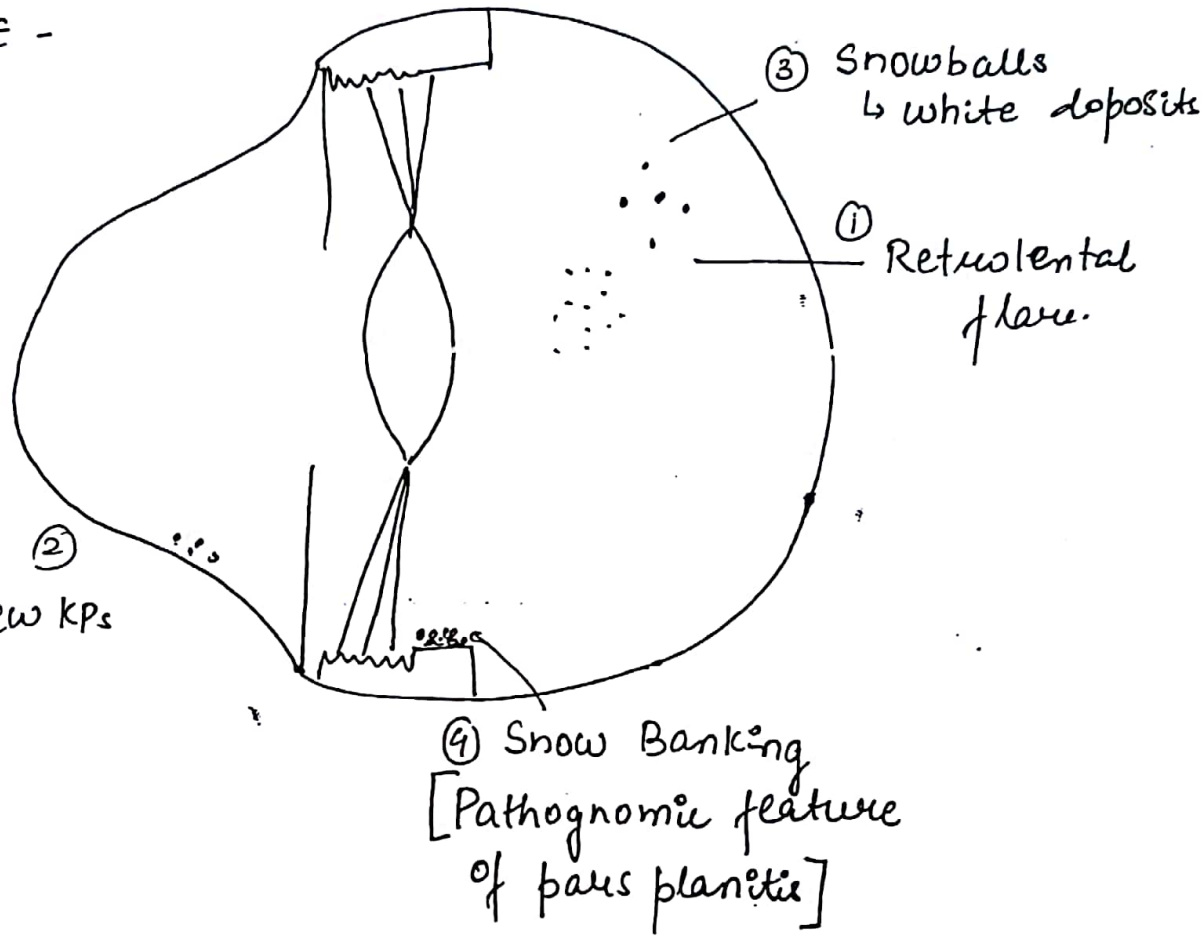


Rx

Indications-
1) if vision goes ↓ < 6/6
2) ↳ it is a/w CME

I → IV step Approach

(I) LOCAL STEROIDS
Subtenon injecⁿ of Triamcinolone acetate
↓
(II) SYSTEMIC STEROIDS
↓
(III) APPLY CRYO corresponding to snow banking
damaging blood supply of snow banking

(IV) PARS PLANA VITRECTOMY

clear blurring of vision

Bulk of inflammation ↓ hence pt respond to t/t now.

C/F

## POSTERIOR UVEITIS

[1 Image]

① CHOROIDITIS
round yellow patches

② VITRITIS

③ Papillitis

④ Retinal edema

⑤ Cystoid Macular Edema

⑥ Periphlebitis
Hallmark feature ⇒ venous sheathing.

Periphlebitis

Rx -

1) Local Steroids
Subtenon inj$^{n}$ of Triamcinolone Acetate

2) Systemic steroids

## DISEASES ASSOCIATED C UVEITIS

1) ARTHRITIS
- HLA-B27 associated
- Sero-negative. - RF ⊖ve
- Non-Granulomatous Anti Uveitis

1) ankylosing spondylitis
2) psoriatic arthritis
3) Reiter's syndrome

TRIAD

a) Urethritis
b) arthritis
c) conjunctivitis.

4) JRA. - early onset pauciarticular sero-neg.

JRA -

arthritis of <16yrs

Classification

- Pauci articular
  - <5 ~~yrs~~ jts
    - Early onset
      - associated c̄ Uveitis
    - Late onset
- Poly articular
  - ≥ ~~5yrs~~ jts
- Systemic onset
  - Still Ds.

Atypical Uveitis → white Uveitis. [in JRA]
↳ 5 features ~~pa~~ absent
↳ No redness

Child presents c̄ complication.

- Complicated cataract
- 2° Glaucoma
- Band shaped Keratopathy Q.

## 2) SARCOIDOSIS

### OCULAR FEATURES

a) Sarcoid nodules on $\boxed{\text{episclera}}$ & $\boxed{\text{sclera.}}$

b) Interstitial keratitis & Band shaped Keratopathy } cornea

c) ~~Granulo~~ Granulomatous Pan Uveitis.

d) Venous sheathing of periphlebitis in sarcoidosis is very thick like candle wax
↳ Candle Wax Dripping Sign [Image] QQ.

Lander's sign:-
Pre-retinal nodules



## 3) BEHCET's Ds / Transient Hypopyon Syndrome

Obliterating vasculitis due to circulating immune complexes.

$\boxed{\begin{array}{l}\text{HLA B5} \\ \text{HLA B51}\end{array}}$

Pt presents c̄ $\boxed{\text{recurrent Hypopyon.}}$

Non-Granulomatous < ant. / post

## 4) EALES Ds / PERIPHLEBITIS RETINAE

- Recurrent Vitreous Haemorrhage
- young ♂
- HSN React towards Tubercular Ag. [Type IV HSN]

O/E - 1) Venous sheathing
2) Vitreous haemorrhage

Rx -
1) Check for active TB
↓
Start ATT if yes.

2) Mx of vitreous haemorrhage

- Partial → Posture management → propped up position for drainage. → Blood doesn't come before macula
- Total → Pars Plana vitrectomy

## 57 HIV

- M/c ocular feature → Microangiopathy
  manifest as
  a) H'ge
  b) Micro aneurysm
  c) Cotton wool spots ← Most Imp
  (Soft exudates)
  ↓
  Composed of axonal debris
- M/c opportunistic Inf" → CMV Retinitis
  ↓
  Sauce / cheese retinopathy (Image)
  H'ge
  Necrosis

| Microaneurysm<br>① Diabetic Retinopathy | Macro aneurysm<br>HTN Retinopathy |
|---|---|

$\gg 100\mu$

* Other opportunistic Infecⁿ :-

1) Toxoplasmosis
2) Pneumocystis carini

} cause choroiditis

3) Herpes zoster → ARN [Acute Retinal Necrosis]

Rx -

1) Anti- HIV Drugs.

Pt is on HAART therapy

↳ H/c ocular S/E ⇒ Immune recovery Uveitis

↓

Non Granulomatous Post. Uveitis (Vitritis)

## 6) TOXOPLASMOSIS

Ant. | Post

Post → Intense Vitritis

QQ. Head Light in fog appearance (Toxo) → Tattoo.

Gr. | Non. Gr.

Presents c̄ Punched out Pigmented Lesion mainly involving Macular area (Image)

Rx → Clindamycin.

## 7> SYPHILIS

Ant. | Post

Post → Diffuse chorioretinitis → Salt & Pepper Fundus
Post → Localised choroiditis → Juxta-papillary Choroiditis

Gr. | Non. Gr.

IRIS ROSEOLA

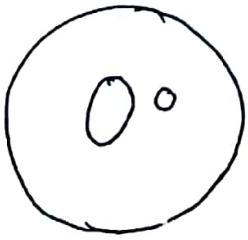

Rx - Penicillin

## 8> TB

Granulomatous Panuveitis

M/c Ocular → Uveitis

M/c allergic → Phlebtenular Keratoconjunctivitis [Type IV HSN]

Rx - ATT.

## 9> VKH [Vogt Koyanagi Harada Syndrome]

Granulomatous Panuveitis + Systemic Features

HLA-DR4

1) encephalitis — VV TAEP
2) Vestibular Dysfunc
3) Tinnitus
4) Alopecia
5) Vitiligo (Suguiras sign)
6) Poliosis

Uveitis + encephalitis ⇒ VKH Syndrome.

## 107 SYMPATHETIC OPHTHALMITIS

Perforating injury in 1 eye causing uveitis in the othe eye

↓

causing autoimmune reac" in uveal tissue

↓

Never before 2 weeks.

Max. cases manifest bet" 2 weeks to 3 months

Granulomatous Panuveitis




1st sign of → Retrolental flare

1st symptom → Difficulty in near vision

Dangerous area of Eye :- CILIARY BODY

↓

Bcoz. any trauma to ciliary body is a big risk of sympathetic ophthalmitis

## 117 FUCH's HETEROCHROMIC CYCLITIS

- Atypical Ant Uveitis
- Non-Gr Ant. Uveitis.
- U/L → characterised by Heterochromic Iridis

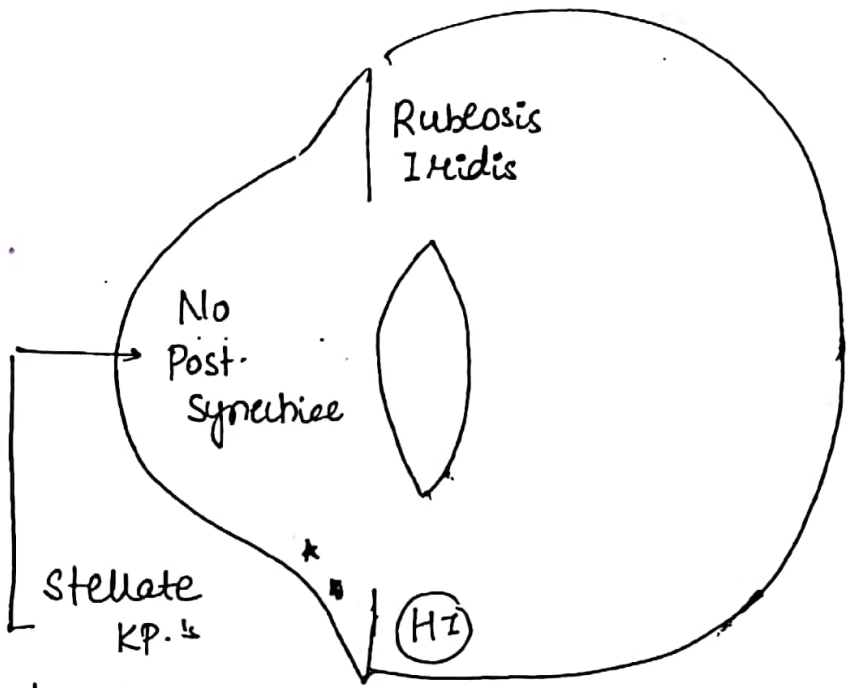


No role of Steroids & Cycloplegics.

Pt. presents c̄ — complicated cataract
— 2° Glaucoma.

$\boxed{\text{IOL is C/I in JRA.}}$

## 127 ONCHOCERCIASIS

RIVER BLINDNESS

caused by Onchocerca Volvulus

Non-Granulomatous : Ant / Post

cause of Blindness - Sclerosing Keratitis
It is included in Vision 2020.

℞ - Ivermectin.

13) OPHTHALMIA NODOSUM

- Due to intense Granulomatous inflammation
- Due to Caterpillar Hair in Eye

## VISION 2020

WHO programme to control 5 Disease by 2020.

INDIA

1) Cataract
2) Trachoma
3) Onchocerciasis
4) Childhood Blindness
5) Refractive Errors

No onchocerciasis

+

3 < DM, Glaucoma, Corneal Blindness

LEPROSY:- Ocular involvement more in Lepromatous Leprosy than tuberculoid leprosy.
Iris Pearls - pathognomic feature.

# CONJUNCTIVA

Thin mucous membrane over the ocular surface

## CONJUNCTIVITIS

Inflammation of conjunctiva

C/F :- (5) features. + F.B. sensation + Discomfort to eye.

Redness - Conjunctival

D/C - depends on etiology.

Bacterial ⇒ Purulent

Chlamydial ⇒ Mucopurulent

Viral } ⇒ Watery.
Allergic }

Pathology

Follicular → formation of follicles → aggregation of lymphoid cell

Papillary → Epithelial Hyperplasia

T/t

B } → Antibiotic
C }

V ⟶ Antibiotic to prevent 2° infn

A ⟶ antiallergics + steroids (mild)

## MEMBRANOUS CONJUNCTIVITIES

All features + Membrane formation.

- Bleeds on peeling. Q
- cause - Corynybacterium Q. Diphtheriae

## PSEUDOMEMBRANOUS CONJUNCTIVITIES

All features + Membrane formation.
↳ doesn't bleed on peeling

cause → 1) mild diphtheriae
2) severe adenoviral infn
3) streptococcus haemolyticus.

## ANGULAR CONJUNCTIVITIES

Conjunctivitis at 2 canthi ~ excoriation of skin.

causes - 1> Moraxella Axenfield Q
" Lacunata
" Catarrhalis

2> Staph aureus

Rx Antibiotic Drops
Q ZnO → inhibits proteolytic enzymes

## HAEMORRHAGIC CONJUNCTIVITIES

$ Conjunctivitis + Subconjunctival haemorrhage

Cause

Q Bacterial — Pneumococcus, Haemophilus

Viral Q.

1) Enterovirus - 70
2) Adenovirus
3) Coxsackie 24
4) Echovirus 34

**CAUSES OF SUBCONJUNCTIVAL HAEMORRHAGE**

1) Haemorrhagic Conjunctivitis
2) Trauma
3) HTN
3) Bleeding Diathesis
4) Whooping Cough.

# TRACHOMA

Chronic conjunctivitis of children

Age - 1-9yrs

Cause - Chlamydia A, B, Ba, C Q.

Chlamydia D to K ⇒ Adult Inclusion Conjunctivitis

or

Q Swimming pool conjunctivitis

↳ It is also caused by adenovirus.

C/F - Itching
watering

O/E - sagogram
1) Follicles on the upper palpebral conjunctiva.
2) follicle on upper limbus ⇒ Herbert's follicle




3) Arlt's Line - Linear scarring on Upper palpebral conjunctiva

4) Herbert's pit - scarring on Herbert's follicles. (upper limbus).

## WHO classification

F → Follicle
No. ≥ 5 follicles
Upper palpebral conjunctiva.

I → Inflammatory stage
Itching
watering

S → Scarring
Arlt's Line
Herbert's pits

T → Trichiasis
misdirection of eyelash

O → corneal opacity

Complication of Trachoma ⇒ Corneal Ulcer

Pathology

Both follicular + papillary reac$^{n}$

Intracytoplasmic inclusion bodies
↓
HP Bodies
[Halberstaedter Prowazeki].

Community ophthalmology
→ SAFE Strategy
WHO programme to control Trachoma
S - Surgery → only trichiasis Sx
A - Antibiotics →
F - Facial hygiene
E - Environmental cleanliness

Azithromycin
1g in adults.
20mg/kg children.

Topical Tetracycline
1% ointment

Atropine ointment i also 1%

Prevalence of Trachoma follicles in Age group 1-9yr
if >10% ⇒ follow SAFE. Strategy
5-10% ⇒ F & E.

< 5% - Nothing is done.

→ Vision 2020 programme

DOC for Blanket therapy ⇒ AZITHROMYCIN.
↳ for prevention

℞ - DOC → AZITHROMYCIN QQ

Other options - 1) Tetracyclin
2) Sulphacetamide eyedrops

## ALLERGIC CONJUNCTIVITIES

### PHYLCTENULAR KERATO CONJUNCTIVITIES

Endogeneous antigen.
1) Staph aureus
2) TB

C/F
- Itching
- Watering

O/E
Phylecten at Limbus

( When cornea is involved
Fascicular Ulcer.

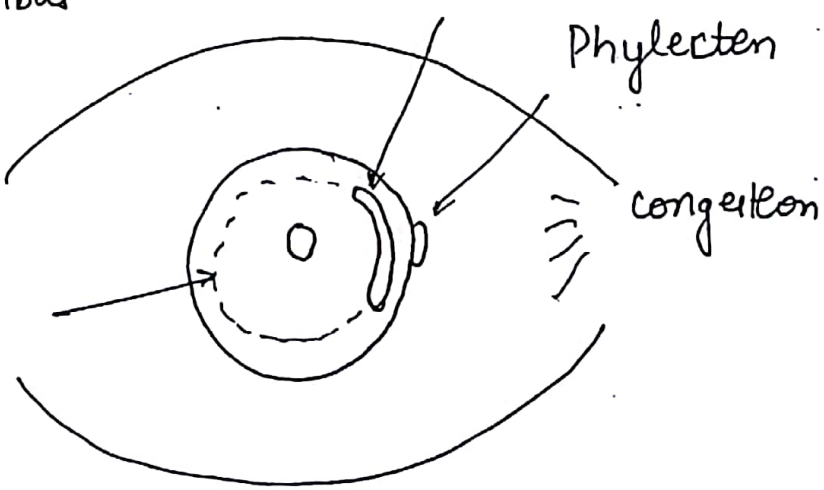


Fascicular ulcer
Later forms → Ring ulcer

Type IV HSN (P)

Rx ① OLOPATADINE ② EPINASTIN ] → Mast cell stabilizer + Antihistaminic

③ Na cromoglycate - mast cell stabilizer

④ Steroids - fluoromethalone

# VERNAL KERATOCONJUNCTIVITIS
## or
## SPRING CATARRH

1) Disease of summer

2) - Age group - ♂ children

3) Exogeneous Antigen. → Dust, Pollen.

4) No follicular Reac$^{n}$.

C/F- → Itching, Watering + Ropy Discharge

↓

fibrin thread in D/c

looks like arcus

O/E- ↓

Pseudogerontoxon or Cullid's bow (Opacity on cornea)

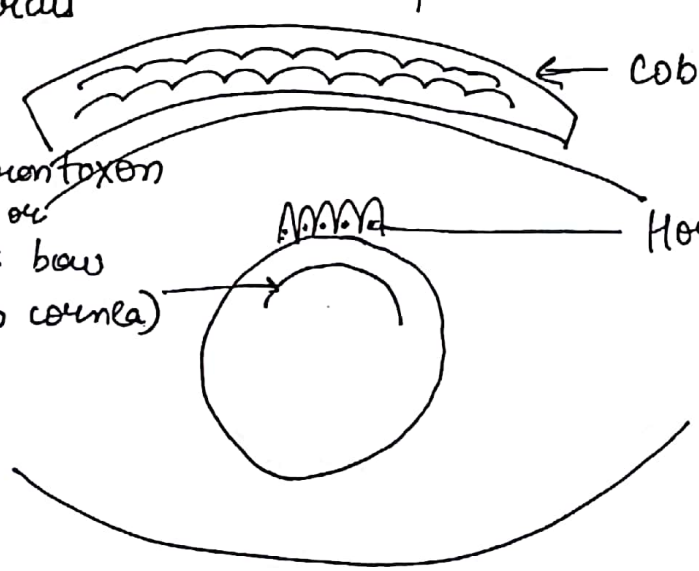

← cobblestone appearance

Hornor Trante's spots → eosinophils

↓

Type I HSN ®

Maxwell- Lyon sign
true eosinophils in Ropy D/c

Rx - same as phlyctenular

# OPHTHALMIA NEONATORUM

## NEONATAL CONJUNCTIVITIES

Defined as conjunctivities in 1 month of age

Cause-

1) Chlamydia → H/c cause → 4-10 day
2) Gonorrhoea → 2-4 days
3) chemical conjunctivities
4) Herpes simplex virus.
5) Staph aureus

CREDES METHOD-

1% $AgNO_3$ in (B) eyes to prevent Gonorrhoeal Conjunctivities
Not followed now as it causes chemical conjunctivities

# VITAMIN-A DEFICIENCY

## XEROPHTHALMIA

Conjunctival xerosis.

TYPES

- EPITHELIAL XEROSES
  - xerophthalmia.
- PARENCHYMATOUS XEROSES
  - all cause of Scarring conjunctival.
    - → Trachoma
    - → all types of burn (chemical, thermal, electrical, radiational)
    - → Steven Johnson Syndrome

Alkali is more dangerous as it can penetrate eye

## XEROPHTHALMIA

* WHO GRADING

$X_N$ → Nyctalopia / Night Blindness

$X\,I_A$ → Conjunctival xerosis

$I_B$ → Bitot's spots

$X\,II$ → Corneal xerosis

$X\,III_A$ → Keratomalacia $< \frac{1}{3}^{rd}$ of cornea

B → " $> \frac{1}{3}^{rd}$

$X_S$ → Corneal scarring

$X_F$ → Xerophthalmic Fundus (White spotted Fundus)

Q. Earliest feature of vit A Def$^n$ - Nyctalopia

Q. Bitot's spot more common c side → temporally

* 2° signs -

$X_N$ ✓ (rest are 1° signs)

$X_S$ ✓

$X_F$ ✓

℞ >1yr = Inj$^{n}$ vit A 1 lakh IU 0, 1, 14 days.

<1yr = Half the dose

## PTERYGIUM

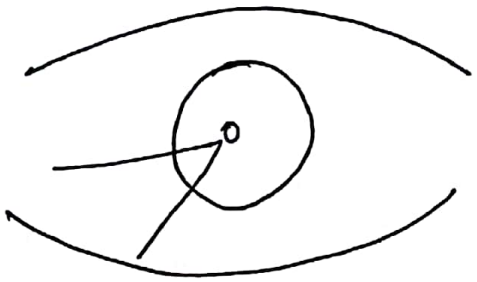

Subconjunctival fibrovascular tissue encroaching the cornea.

Q. Not Inflammatory. It is connective tissue disorder.

Q. M/c side → Nasal.

### ETIOLOGY

Due to exposure to UVB rays

### c/F-

1) Cosmetic
2) Astigmatism → curvature is affected
3) If encroaches pupil → lead to diminution of vision.

℞

→ Excision

. Recurrence is main challenge

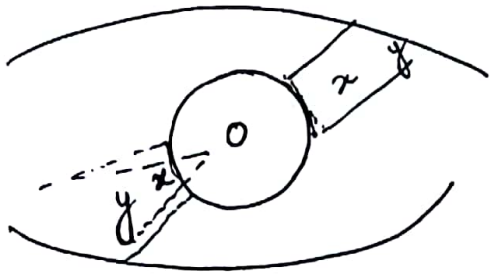


Bare sclera Technique → High Rate of Recurrence

↓

Prevent Recurrence

- Mitomycin-C
- Autografting (Best method)

PERFECT Surgery :-

[Pterygium extended Resection Followed by Extended Conjunctival Transplantation].

Recurrence = 0.

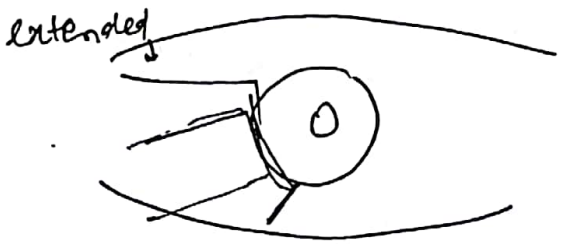


| Pterygium | GLASS ROD TEST | Pseudopterygium |
|---|---|---|
| Not passed | | Glass rod passes easily |

# DRY EYE



## LAYERS OF TEAR

1) Lipid Layer → By meibomian Gland → helps to prevent evaporation of tear.

2) Aqueous → secreted by Lacrimal & Acc. lacrimal helps in lubrication

3) Mucin (Innermost) → from Goblet cells Q.
   - helps to spread tear on ocular surface
   - Max. Goblet cells
     - Inferonasal conjunctiva

Deficiency of any of the 3 layers = Dry Eye

## ✱ KERATOCONJUNCTIVITIES SICCA (KCS)

Deficiency of AQUEOUS Layer.

KCS + Xerostomia = 1°

↓

1° Sjogren's Syndrome

+

Connective tissue Disorder

↓

2° Sjogren's Syndrome

C/F →

1) Burning sensation
2) Gritty sensation
3) severe → Precorneal Tear film ⇒ D/W



# Inv.



1) SCHIRMER's TEST :-

Tear strip is put under lower lid for 5 mins

Any wetting of $\boxed{< 5\ mm}$ = severe Dry eye

2) TEAR FILM BREAK UP TIME :- (BUT)

From Last Blink, how much time is taken for 1st dry spot to appear

Last Blink




If <10 sec → Dry eye

3) ROSE BENGAL STAIN :-

stains dead cells, mucus

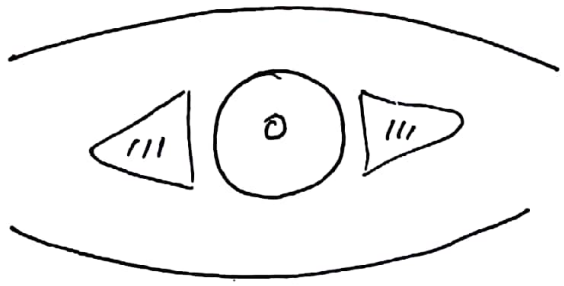

4) TEAR OSMOLALITY -

↑ sed in patients of Dry eye

AIIMS 00

PHENOL RED DYE Test :- measures the produc$^n$ of tears c̄ out topical anaesthesia, as the dye changes its colour to red on contact c̄ tears. It doesn't require pH meter for reading the result

Rx

**MEDICAL**

↓

Lubricatory Eye Drop

↓

Methyl cellulose derivatives

**SURGICAL**

Lacrimal punctal occlusion.

# LACRIMAL DRAINAGE SYSTEM



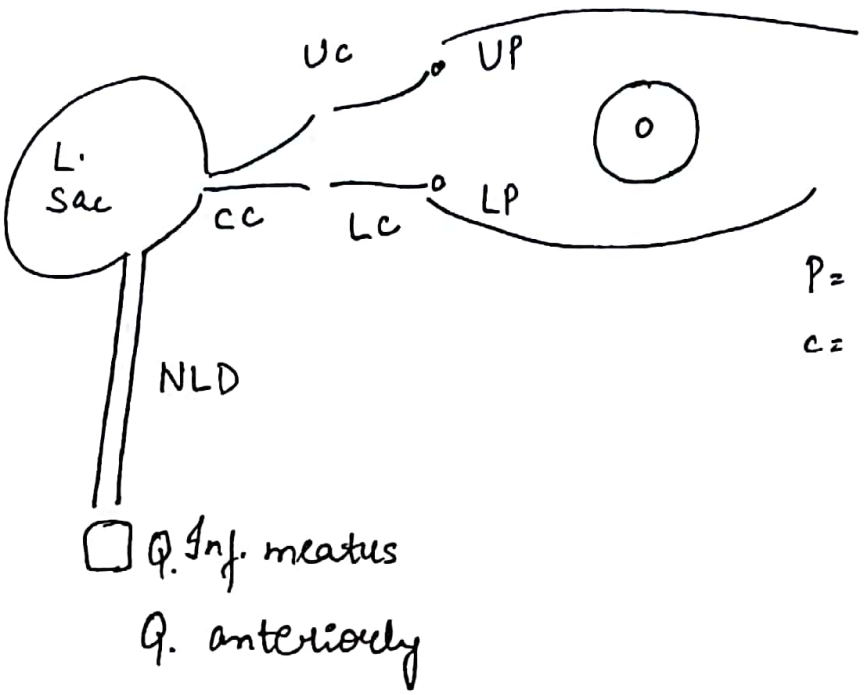


Q. On closing eyes → arrangement of puncta
↓
UP is medial to LP.

WATERING

Due to overproduc" → LACRIMATION

overflow → EPIPHORA.

* whenever drainage system blocked ⟷ Epiphora / Discharge.

Inv -

1) Regurgitation Test -
pressing on medial canthus, when water + pus regurgitate, test is +ve.

2) Syringing -

→ If regurgitation is from opposite punctc
↳ indicate blockage in common canaliculc & forward

— If regurgitation is from same punctc
↳ punctc itself is blocked

→ partial obstruction can be opened by syringing

3) Dacrocystography
Inject dye in tear
↓
Radiography

4) Dacryoscintillography -
Radioactive dye is used.

## DACRYOCYSTITIS

Inflammation of lacrimal sac.

- CONGENITAL
- ACQUIRED
  - ACUTE
  - CHRONIC

# CONGENITAL DACRYOCYSTITIS



ETI- due to non-canalisation of NLD.

C/F - epiphora
Discharge

Rx - < 6 months → Massaging ± antibiotic eye drops (CRIEGLERS MASSAGE)

6-18 months → Best result - is by Probing.

>18 month → Best result is by DCR

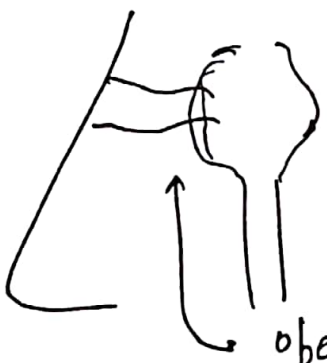

Dacryocystorhinostomy

opening is made in Middle Q. meatus.

Q. DCR → from 4yr onwards. → 70yr

↓

>70yr - atrophy of nasal mucosa

Q. When does tear Production starts?

6 weeks. → (Reflex tear production.)

# ACQUIRED DACRYOCYSTITIS

## ACUTE

C/F. → Epiphora
→ Discharge
→ Acute Inflammation

Rx - control Inflammation ī antibiotics / anti-~~allergy~~ inflammatory.
↓
DCR

Q. Sequelae → Lacrimal fistula
↓
Rx = DCR.

Q M/c. etiological agent → Staph. aureus.

## CHRONIC

Q ♀ > ♂

Q. M/c etiological agent - Staph. aureus > strepto. pneumoniae

C/F- epiphora
D/S

Rx - DCR.

Sequelae → Mucocele formation.
↓ infected
Pyocele formation
↓
Lacrimal fibrosis

Rx of Lacrimal fibrosis → Dacryocystectomy

Q. M/c ocular feature of MUMPS?
⇒ Dacryocystoadenitis.

Q. M/c ocular feature of MEASLES?
⇒ Vit. A Deficiency

Q. SNOW BLINDNESS/ PHOTOOPHTHALMIA ?
→ Injury by UV B rays.
→ Reflection from snow

C/F- corneal epithelial necrosis

Rx- Pad + Bandage ī antibiotic ointment

Q. PHOTO - RETINITIS ?
→ Injury by Infra-red rays
→ Directly looking at Solar eclipse ī unaided eye
→ C/F- Macular Burn.
↓
Macular scar.

No effective Rx.

# CAUSES OF NYCTALOPIA

1> Vit A Deficiency

2> Retinitis Pigmentosa

3> High Myopia (>6D)

4) Late stage of POAG.

5) **Oguchi's Disease**
   - ↳ Congenital stationary Nt. Blindness
   - Pale fundus
   - Mizou's phenomenon
     - ↳ Sitting 1 hour in dark
     - No night Blindness
     - Fundus is (N)
     - Occurs due to overstimulation of rods

6) Choroideremia } choroidal dystrophy
7) Gyrate atrophy }
   - ↳ due to Def" of Ornithine aminotransferase or transcarbamoylase

Fundus exam" → 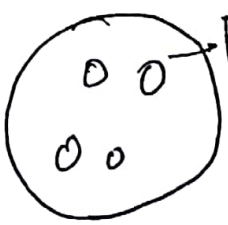 atrophic patches on choroid

$R_x$ → Arginine free diet

# CAUSES OF HAMARLOPIA (Day Blindness)

1> Central corneal opacity

2> " lenticular "

3> ~~Conjun~~ congenital absence of cones

4>

# NEURO- OPHTHALMOLOGY



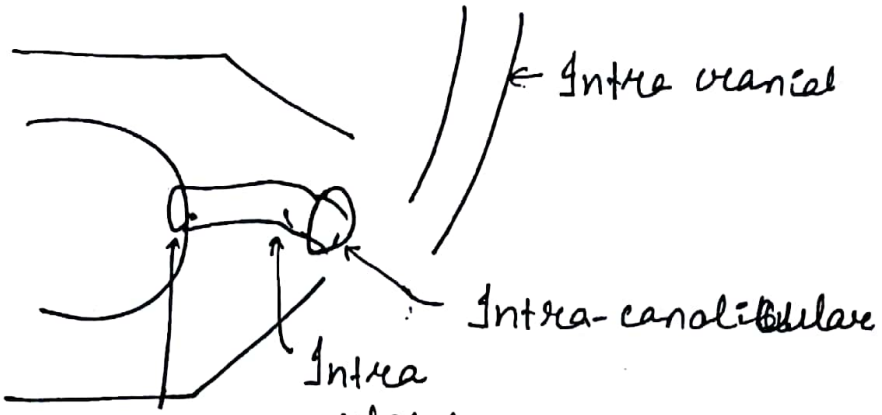


Intra Ocular (shortest) (1mm)

Intra orbital (Longest Part) (2.5 - 3cm)

Q. Structures passing through optic canal

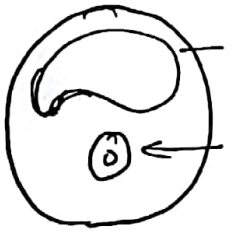


Q. Sup. div. III Nasociliary n/v Abducent n/v Inf Div. of IIIrd




annulus of Zinn
↳ origin of all 4 recti.

N/v s → L Lacrimal
F Frontal
T Trochlear

LR 6 SO 4 → LPS m/s

SR → by sup. div. of III rd n/v

MR, IR, IO → by Inf. div of III rd n/v

# OPTIC NEURITIS

[Optic n/v Disease]

Defn- Pathological condn of ~~optic~~ optic n/v where n/v impulse transmission is hampered

C/F :-

1) ↓ visual acquity
2) Visual field Defects
   - Central Scotoma
3) Afferent Pupillary Defect – 1st Sign
   (Something away from (N) pupillary rear
4) ↓ Color ~~Brightness~~.
5) ↓ Brightness

# CLASSIFICATION

## ANATOMICALLY

- PAPILLITIS
  - Blurred disc margin
- RETRO-BULBAR NEURITIS
  - Fundus - (N)
  - Pathognomic feature
    - RAPD
      - Diagnosed by swinging flash light test
      - Marcus-Gunn Pupil
    - Pain on elevation.
      - sup. rectus has connect ~ myelin sheath of optic n/v
      - on elevation → m/s stretched → cause pain.
- NEURO-RETINITIS
  - Papilla
  - Macular star (deposition of hard exudates)

## ETIOLOGICAL

1) Inflammatory
2) Degenerative
3) Autoimmune
4) Hereditary
5) Ischaemic

**Q AIIMS**

Most likely Δ in the pt who presents ~ painful v/l dimness of vision ~ h/o of persistence of after image: Retrobulbar neuritis

# ETIOLOGICAL

1) INFLAMMATORY –
All causes of post uveitis.

2) DEGENERATIVE –

Multiple Sclerosis

Toxic amblyopia Q

Cause
1) Tobacco
2) Ethambutol
3) Chloroquine
4) Ethyl alcohol
5) Methyl alcohol

## TOBACCO

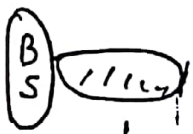


Bs – Blind spot

Centro-caecal Q.
Scotoma

## METHYL ALCOHOL

Directly damages ganglion cell.
hence more dangerous.

## Ocular effects of chloroquine

- Post. Subcapsular cataract
- Optic neuritis
- Bull's eye Maculopathy
- Vortex keratopathy

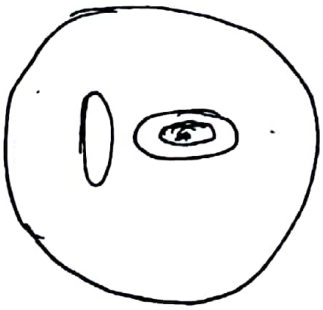



whorl-like / v-shaped

Cornea verticillata } other name

### * Other causes of Vortex Keratopathy -

1) chloroquine
2) Amiodarone
3) Tamoxifen
4) Indomethacin
5) Fabry's Disease
6) Chlorpromazine ✓ all except.

[CAT In Fab Colour]

### 3) AUTOIMMUNE OPTIC NEURITIS -

optic neuritis in all connective tissue Disorder

### 4) ISCHAEMIC ON -

AION → Ant Ischaemic optic neuropathy

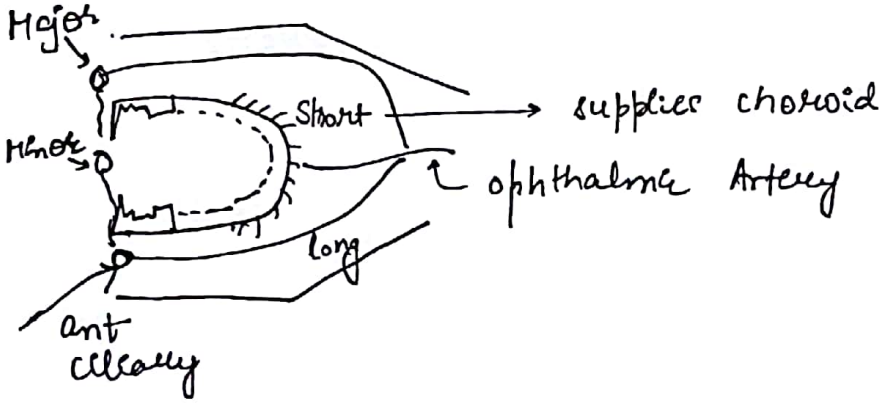

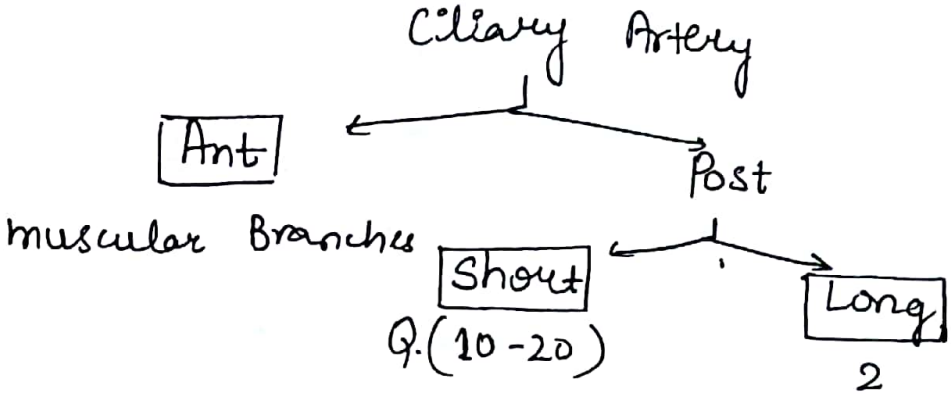


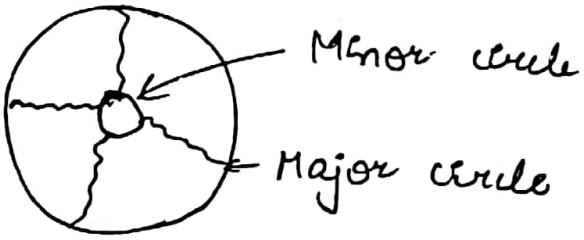


Inner 6th Layer of Retina ⇒ supplied by Central Retinal artery

Outer 4 Layer of Retina ⇒ supplied by short post-ciliary artery

A. Ant. Ischaemic Optic Neuritis

Due to blockage of short Post. Ciliary artery

| ARTERITIC | NON-arteritic |
|---|---|
| Etio - Giant cell arteritis | Etio - ⊗ |
| | Major R/F = HTN ↓ (Nocturnal Hypotension) |

| ARTERITIC | NON-ARTERITIC |
|---|---|
| 1) Sudden painful D/V<br>Visual acquity ↓↓↓ | 1) Sudden painless D/V<br>Visual acquity ↓ |
| 2) Amaurosis fugax<br>transient loss of vision | 2) Altitudinal field Defect |

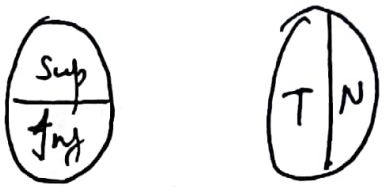


O/E

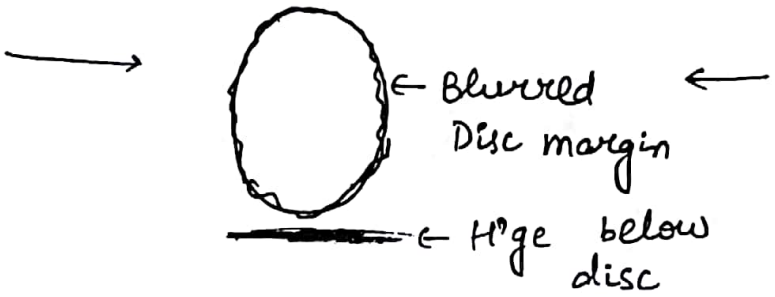


℞ I.V. steroids for 4-5day

↓

Oral steroids

5) HEREDITARY OPTIC NEURITIS/ LEBER's Hereditary optic neuretic

Mutation in maternal mitochondrial DNA

C/F - (R) Optic N. —followed by→ (L) O.N. in other eye.

optic atrophy ⟶ optic atrophy.

NO APD

O/E.

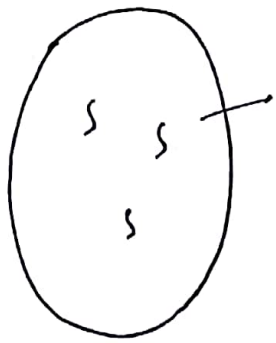


→ Telangectatic vessels on disc

No effective Rx.

# PAPILLOEDEMA

Oedema around disc.

C/F- 1) visual acquity (N)

2) Pupillary Reac$^{n}$ (N)

3) Colour (N)

4) Brightness (N)

5) Visual Field Defect-

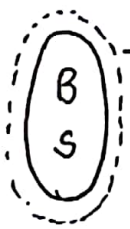


→ Q. enlargement of Blind spot

BS - Blind spot

1st sign of papillodema → Venous dilatation



→ Blurred disc margin.

Rx- Rx the cause

## CAUSES -

## PATHOPHYSIOLOGY

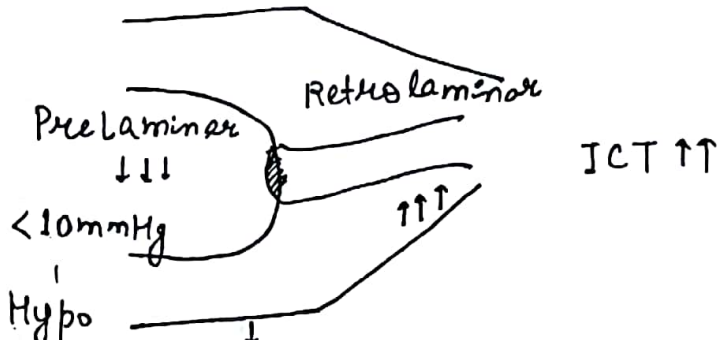


↓

Disturbance of pressure gradient across Lamina cribrosa

↓

Stasis of axoplasmic flow

↓

swelling of axons

↓

Pressure on veins

↓

Leakage

## ETIOLOGIES

(I) INTRAOCULAR CAUSE

Any cause of Hypotony

- Trauma
- Surgery
- Chr. uveitis → Ciliary shutdown.

(II) INTRAORBITAL CAUSE

↑↑ Pressure in orbit

- Inflammation
- Tumour
- Thyroid disease

(III) INTRACRANIAL CAUSE.

↑ ICT

- Tumour
- Encephalitis
- Abscess
- Benign HTN
- Pseudotumour cerebri

↓

↑ ICT → B/L papilloedema

CT scan / MRI (N)

CSF (N)

⇒ Imbalance of formation, Reabsorption of CSF

Causes

1) Obesity
2) Vit A toxicity
3) OCPs
4) Tetracycline

(IV) SYSTEMIC CAUSE-

- MALIGNANT HTN
- SEVERE ANAEMIA

# OPTIC ATROPHY

→ All n/v fibres are damaged

→ Pt - Blind

→ TAPD (Total afferent Pupillary Defect)

## CLASSIFICATION

| 1° | 2° | Consequetive | Glaucomatous |
|---|---|---|---|
| Cause Brain | optic n/v | Retina | Glaucoma |
|  |  |  |  |
| Clear disc margin | Blurred disc margin | clear margin | Upping nasal shifting |
| Chalky white | Dirty white | Waxy disc | |
| Multiple sclerosis | Papillitis | Retinitis Pigmentosa | Glaucoma |
| Neurosyphilis | Papilloedema | Diffuse choroidretinitis | |

## (N) PUPILLARY REACTIONS

▷ LIGHT REFLEX-

Light → Constrict$^{n}$ of Pupil

→ Direct

→ Consensual

2) NEAR REFLEX / ACCOMODATION REFLEX :-

Convergence + Miosis → Accomodation.

3) PSYCHOSENSORY REFLEX :-

Anxiety ⟶ Dilatation of Pupil

↳ Dilator Pupillae → Sympathetic

↳ Iris sphincter → Parasympathetic

## Ab (N) PUPILLARY REACTIONS

1) RAPD

↳ Retrobulbar Neuritis

↳ By swinging flashlight Test

↳ also called Marcus Gunn Pupil

2) TAPD – PR (−)

↳ Optic atrophy

3) Argyl Robertson Pupil

Light - Near Dissociation.

Accomodation Reflex +nt, Lt Reflex (−)

due to Lesion in "Pretectal Nucleus"

Neurosyphillis.

4) HOLMES - ADIE / TONIC PUPIL :-

C/F - 1) Sluggish Light Reflex
2) " Accomodation Reflex
3) " Tendon Reflex.

Q. Position of Pupil → "MID - DILATED"
Vermiform movement of iris seen.

5) HORNER SYNDROME

Lesion of "sympathetic chain."

C/F → 1) Ptosis
2) ↳ mild

LPS → III rd n/v
Muller → sympathetic
↓
2mm of lid elevated

2) Miosis
↳ due to uninhibited action of iris sphincter

3) Enophthalmos
↳ due to ptosis. , apparent enophthalmos.

4) Anhydrosis
↳ loss of sweating

5) Loss of cilio-spinal reflex
↳ Pinching @ nape causes dilatation of pupil

Best described by → ① Ptosis + ② Miosis

Q. Horner's (B) Congenital & Acquired

Congenital → Heterochromia Iridis.

## PUPILLARY LIGHT REFLEX PATHWAY

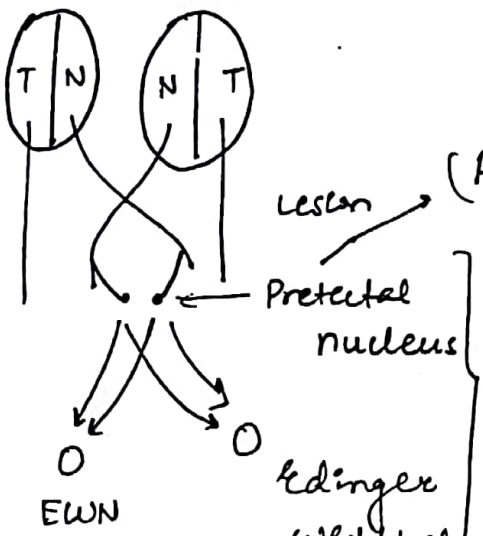


EFFERENT

III rd N/v

↓

Inf. Div

↓

N/v to Inf. oblique (Q)

↓

HOLMES ADIE PUPIL Lesion

Ciliary Ganglion

↓

Short ciliary N/v

↓

Iris sphincter

* 2 Internal m/s supplied by III rd n/v

1) Iris sphincter

2) Ciliary m/s

# LESIONS OF VISUAL PATHWAY

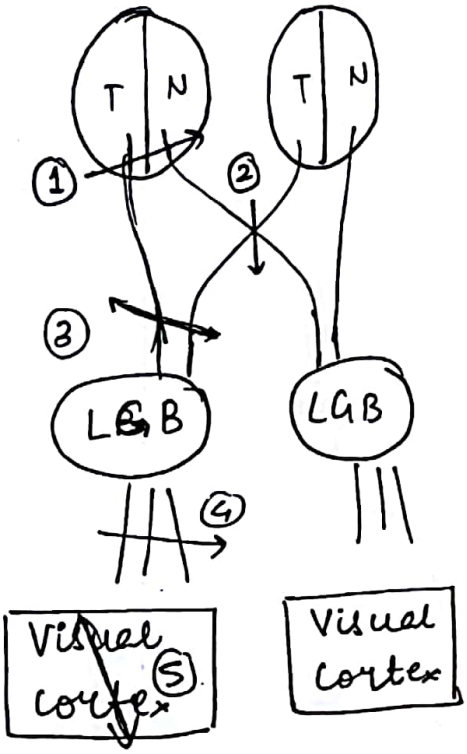


① Ipsilateral Blindness

②

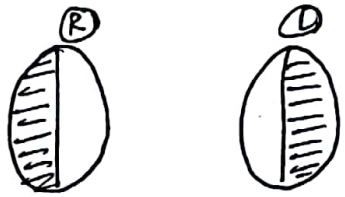


Bitemporal Hemianopia / Heteronymous

③




Incongruous Homonymous Hemianopia

↓

Scotoma not in continuity

④

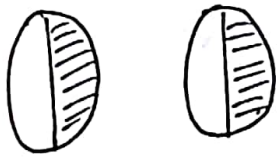

Incongruens. / congruous. Homonymous Hemianopia

⑤

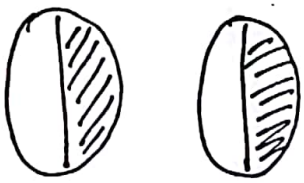

Congruens Homonymous Hemianopia

only Lesions ⑤ are Heteronymous = CHIASMAL

Chiasma is affected in Pituitary Adenomas
Craniopharyngiomas
Aneurysm circle of Willis.

## WERNICKE'S HEMIANOPIC PUPIL :-

feature of optic tract Lesion.

Radiation Lesion :
Cortical Blindness
Pupillary Reac" are
(N)

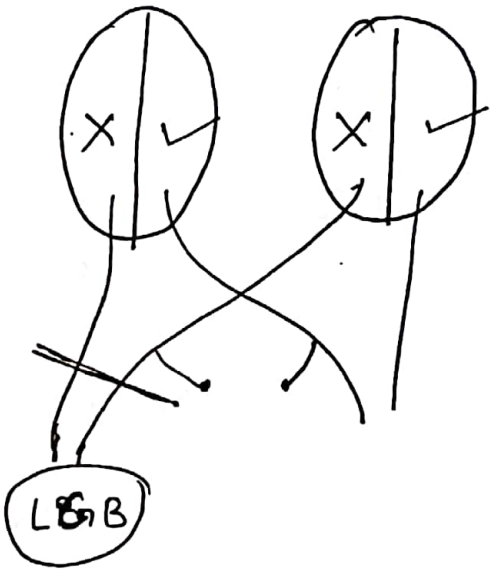


OPTC RADIATION

fibres passing through

Temporal lobe
↓
Inferior fibres
(MEYERS LOOP)



← sup. quadrantopia
[Pie-in sky]

Parietal Lobe
↓
Superior fibres
(BAUMS LOOP)

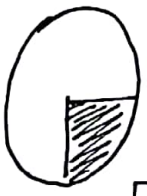

Inf. quadrantopia
[Pie in floor]

# VISUAL CORTEX

suppleed by

- Post. cerebral Artery
  - 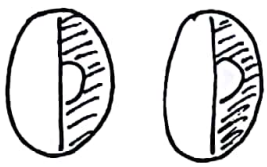
  - Macular sparing Hemianopia
  - (B) side PCA gone
  - 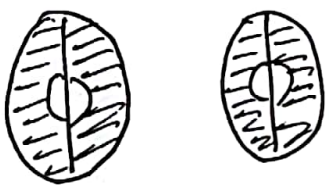
  - Keyhole / vision Tunnel
- Middle cerebral Artery
  - supplies Macular area
  - 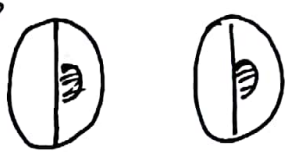
  - Total macular H.H. seen when there is direct trauma to macular area
  - Not seen in vascular blockage as (B) arteries supply macula

- 1°
  - 17, .
- 2°
  - 18, 19
  - visual association areas.

I

II

III

$\boxed{\text{IV}}$ → Thickest Layer. a, b, $C_\alpha$, $C_\beta$

V

VI

Q. Max. optic Radiation fibre terminate in Layer IV of visual cortex.

## LATERAL GENICULATE BODY

I, II ] Magnocellular

III, IV, V, VI ] Parvocellular.

Q
1, 4, 6 → C/L supply
2, 3, 5 - I/L supply

Q
AIIMS Q
Keyhole visual field Defect



## HORIZONTAL GAZE CENTRE

YOLK M/s → C/L Synergists.
M/s of Diff eye → ~~sat~~ synergising action

Horizontal Gaze centre → PONS. - PPRF
(Paramedian Pontine Reticular Formation)

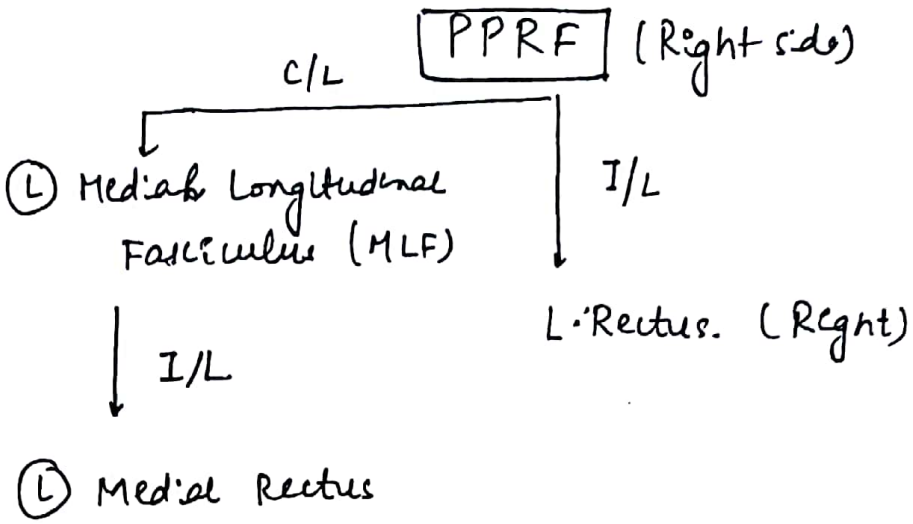


? Any Lesion of MLF → Internuclear ophthalmoplegia (INO)

## INO

1) Defective I/L adduc$^{n}$ ( Medial Rectus won't work due to Lesion of MLF)

2) C/L abducting eye shows ataxic nystagmus

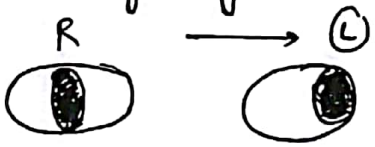


Lesion of (R) side

## III$^{rd}$ NERVE PALSY

1) Down + Out + Intorted

Depressed + Abducted

2) Defective / Restricted ocular movement

3) Ptosis

4) Fixed & dilated Pupil

5) Accomodation — absent

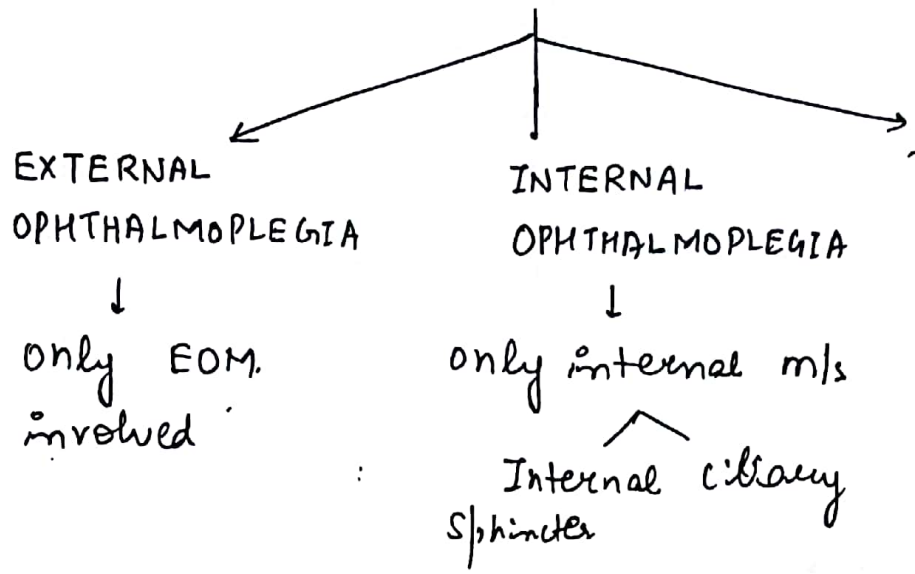


Q. WEBER's SYNDROME

III rd N/V Palsy + C/L Hemiplegia

Q. BENEDICKTS SYNDROME

III rd N/V Paley + C/L Hemitremors

Q MIYARD - GUBLER SYNDROME

6th N/V Paley + C/L Hemiplegia

Q FOSTER - KENNEDY SYNDROME

→ IL optic atrophy

→ CL Papilloedema

Frontal lobe Tx × olfactory groove Tumours

# NYSTAGMUS

Involuntary To & Fro Movement of Eye

- ANATOMICALLY
  - PENDULUM
  - JERKY
  - MIXED
- ETIOLOGICALLY
  - PHYSIOLOGICAL
  - PATHOLOGICAL
    - Sensory Deprivation.
    - Motor Imbalance

## PHYSIOLOGICAL

1) Extremes of Gaze

2) Oculovestibular Reflex (COWS)

3) Optokinetic Nystagmus (OKN)

- Saccadic: Fast abrupt movement to reflex object on fovea
- Pursuit: Slow following movement

4) Defective optokinetic Nystagmus
   ↳ Lesion → Parietal Lobe

Q Optokinetic Drum Test -

objective Test to catch malingering Functional Blindness

PATHOLOGICAL

(I) SENSORY DEPRIVATION

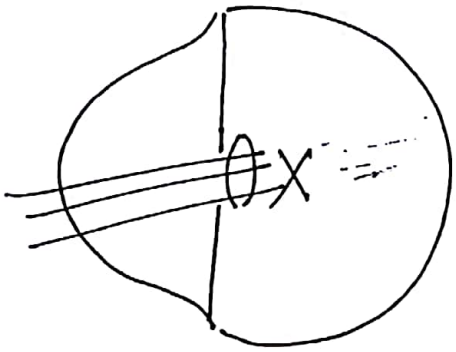

Foveal reflex develop by 5-6month

Opaque media in 5-6 months of age can lead to nystagmus

↓

Pendular

(II) MOTOR IMBALANCE

Q 1) ATAXIC NYSTAGMUS → INO

2) LATENT " → Infantile Esotropia

↓

Convergent squint <1yr of age

Manifest by Cover-Uncover test

3) SPASMUS NUTANS

Nystagmus + Head Nodding

Pendular

4) DOWN BEAT NYSTAGMUS

- Arnold chiari malformation
- Cerebellar Lesions

5) UP BEAT NYSTAGMUS

- Post. Fossa Lesions
- Phenytoin Ingestion

6) SEE-SAW NYSTAGMUS

Seen in chiasmal Lesions. ( Bitemporal Hemianopia)

All are jerky except spasmus nutans

* PASS-POINTING NYSTAGMUS

Nystagmoid movement

feature of cerebellar Lesion

- MINER's NYSTAGMUS

Rotatory

# ORBIT

Q 30cc

Q shape – QUADRILATERAL / PYRAMIDAL

Q weakest wall – MEDIAL WALL
↓
due to cribriform plate of ethmoid sinus
"Lamina papyracea"

Q. BLOW OUT # –
Floor # due to blunt trauma.
M/c site = Medial to Inf. orbital fissure
(Posteromedial part)

## PROPTOSIS

Protrusion of Eyeball –
Lateral orbital margin ⟶ apex of cornea
> 21 mm.

or difference btwen 2 eyes > 2mm

EXOPHTHALMOS – for thyroid disease

EXOPHTHALMOMETER – used for measurement of exophthalmos

Commonest → Hertel's exophthalmometer

In children → Leudde's exophthalmometer

CLASSIFICATION

- UL / BL
- Painful / Painless
- Axial / Non Axial
  - Straight line
  - Different direction

# THYROID OPHTHALMOPATHY / GRAVE'S EYE DISEASE /

→ Autoimmune disease

→ ♀

→ Q. Pt. can be Euthyroid / Hypothyroid / Hyperthyroid

C/F -

1) Ptosis
2) Optic Neuropathy
3) MYOPATHY
4) Soft tissue signs
5) LID Signs

PATHOPHYSIOLOGY -




↳ APD
↳ ↓ visual acuity
↳ ↓ Colour
↳ ↓ Brightness

$R_x$ =

1) Systemic steroids

2) Radiotherapy → ante-inflammatory role of Radio

3) Severe → **Decompression Sx**

↳ Involves breaking orbital wall

Q. sequence of wall to be broken

↓ Medial
↓ Inferior
↓ Lateral

## MYOPATHY

Restrictive Myopathy

C/F → Diplopia
→ Squint

$R_x$ - squint surgery

| |
|---|
| For an underacting m/s ⇒ Resection done |
| For overacting m/s ⇒ Recession |

1st m/s → Inf. Rectus

Last m/s → Inf oblique

Part of m/s involved – Belly

Q. 1st Defective movement → Elevation
as the inf. rectus is fibrosed, it doesn't allow elevation.

FORCED DUCTION TEST-

To differentiate between

Paralytic pathology
↓
Sup. oblique can be elevated by forcep

Restrictive pathology
↓
can't be elevated due to fibrosis.

SOFT TISSUE SIGN

1) edema around eyes

2) chemosis
↳ conj

3) Sup. Limbic Keratoconjunctivitis. Q

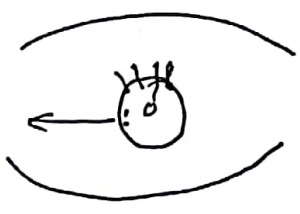


Rx = 1) Adrenaline E/D

2) Acetylcysteine E/D
↳ to dissolve mucus

# LID SIGNS

(N) LOCATION - Upper lid 2mm below limbus
Lower lid touches limbus

Lid signs are due to overaction of LPS m/s

1) DALRYMPLE SIGN → Lid Retraction

2) VON GRAEFE → Lid Lag.

3) KOCHER'S SIGN → staring LOOK.
(extreme lid retraction)

4) STELLWAG SIGN → ↓ frequency of Blinking

$R_x$ - Recession of LPS (overactive m/s t/t by recession)

Q. medical Rx of Lig Lag - GUENETHIDINE E/D.

* SEQUENCE OF Sx Done In THYROID -

D Decompression
↓
S Squint
↓
L Lid surgery

# ORBITAL CELLULITIS

## ANATOMY

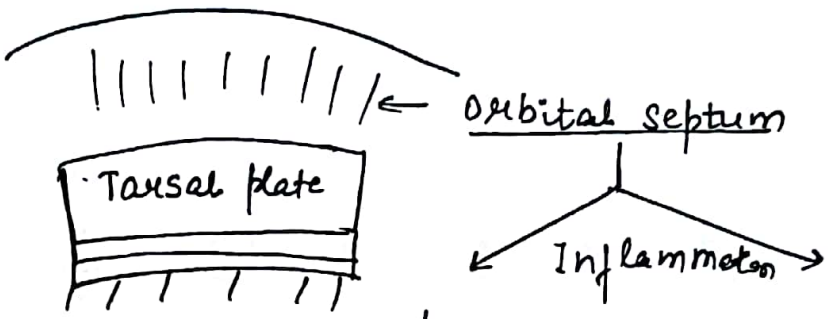


## C/F of ORBITAL CELLULITIS

1) U/L
2) Painful Proptosis
3) Restricted eye movement (Due to proptosis)
   ↳ 3, 4, 6 n/v not involved
4) Fever + malaise

## Rx

Q. Ocular EMERGENCY → Becoz of risk of causing cavernous sinus thrombosis

→ Admit pt
→ start c I/V Antibiotics < aerobic, anaerobic
→ I/V anti-inflammatory

# CAVERNOUS SINUS THROMBOSIS

## ANATOMY

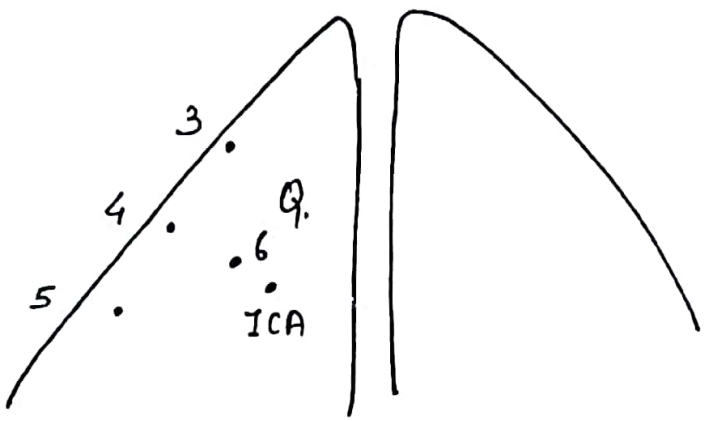


C/F -

1) 1st sign → 6th n/v palsy

2) 3, 4, 6 are involved → causing total restriction of eye movement

3) Absent → L. Reflex

4) Absent → Acc. Reflex.

5) 5th → Absent Blink Reflex

6) B/L Painful Proptosis

7) B/L Papilloedema

8) Mastoid Tenderness.

9) Ptosis all except Q.

Rx 1) IV antibiotics < aerobic / anaerobic

2) IV anti-inflammatory

Prognosis - Poor

## LACRIMAL GLAND TUMOUR.

NON - AXIAL

**BENIGN**

Benign mixed Tx / Pleomorphic adenoma
↑ H/c Tx

**MALIGNANT**

1) Pleomorphic Adeno carcinoma
2) Mucoepidermoid
3) Adenoid-cystic
↳ H/c malignancy
Most dangerous malignancy
↓
due to perineural invasion.

## PULSATING PROPTOSIS

⇒ CAUSES :-

1) Carotico-cavernous fistula (CC). ← H/c
2) # Roof
3) NF-1

} Intracerebral pulsations are transmitted

## INTERMITTENT PROPTOSIS

changes ↕ head posture

Cause - Orbital Varices QQ

ONE - LINERS -

QQ. M/C Intra ocular malignancy

Children → RETINOBLASTOMA

Adults → 1) CHOROIDAL MALIGNANT MELANOMA
2) METASTASIS

Q M/C Intra orbital Malignancy

Children → RHABDOMYOSARCOMA

Adults → NON-HODGKIN's LYMPHOMA
B cell type

Q. M/C Intra-orbital Tx of adults = CAVERNOUS HEMANGIOMA

Capsulated, so easily resected

## OPTIC N/V GLIOMA = ASTROCYTOMA

all Non-neuronal cell of nervous system → Glial cells

EXAMPLES-

1) Oligodendrocytes
2) Astrocytes
3) Neuroglial
4) Microglial etc

**C/F**

1) Disease of childhood
2) More common in ♀
3) U/L
4) very slow growing Tx
5) M/C → NF-1 > 2 Q.

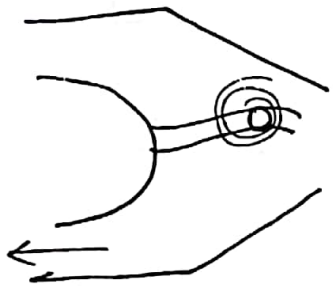

when size of Tm ↑

Proptosis is a Late feature

Initial signs → optic n/v disease

M/C pathological type - Pilocytic astrocytoma

↓

hair like



**Inv** :-

1) MRI
2) CT Scan




**Rx** -

1) Observation
2) Radiotherapy
3) Surgery

# RETINOBLASTOMA

From Neuroectodermal cells → Retinoblasts.

C/F

1) M/c age of presentation - (< 3yrs)
   Commonest → 18 mnths

2) M/c mode of presentation - LEUCOCORIA
   (white eye reflex)
   Amaurotic Cat's Eye Reflex

3) 2nd M/c mode of presentation = STRABISMUS

4) Glaucoma

5) Pseudohypopyon → Tx cells in ant. chamber

6) Pseudo uveitis

7) Orbital cellulitis

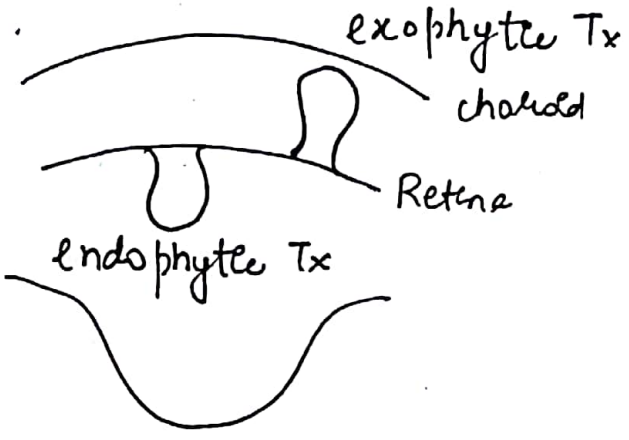

**D/D** -

## PSEUDOGLIOMAS (① → ⑩)

1) Congenital Cataract – M/c cause of Leucocoria
2) cyclitic membrane
3) Fungal endophthalmitis
4) Central choroiditis – Toxocariasis
5) Central coloboma – sclera shine white as central part not formed
6) PHPV
   ↳ persistent hyperplastic 1° vitreous
7) ROP
   ↳ retinopathy of prematurity
8) Coat's Disease
9) Retinal Dysplasia
10) Central Retinal Detachment

Q. Differentiating Pt. Bet^n RB & Pseudoglioma?
Retinoblastoma → IOP ↑
Pseudo glioma → (N)

Q Benign counterpart of RB → RETINOCYTOMA

**Inv** -

Q. 1) 1st Inv → USG (B) scan
2) CT scan – for intracranial extension

3) MRI - for Pinealomas → IOC

4) X-Ray - Rhese view
- optic foramen.

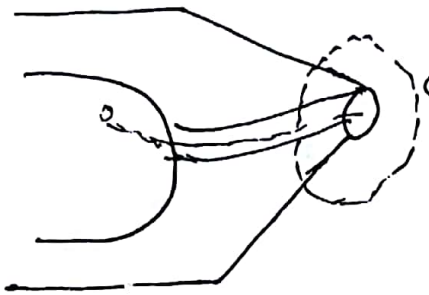

← enlargement of optic foramen

H/c mode of spread - through optic n/v Q AIIMS

5) Estimation of enzymes in aqueous humour
↑↑↑ in RB

| LDH | PGI | NSE |
|---|---|---|
| (Lactose Dehydrogenase) | (Phospho gluco isomerase) | (neuron-specific enolase) |

## PATHOLOGY :-

GROSS -

- Necrosis
- calcification Q

MICROSCOPIC -

- Differentiad
  1) HOMER-WRIGHT
  2) FLEXNER. WINTERSTEINER
  3) FLEURETTES
- Un-differentiated

# GENETICS



1) QQ. M/c mutation = 13q




2) THilateral RB
= B/L RB + Pinealoma

## KNUDSONS TWO-HIT HYPOTHESIS

Somatic + Somatic → Sporadic / Non-Hereditary (94%)

Somatic + Germ cell → Hereditary (6%)
→ B/L
→ multicentric
→ associated ± other non-ocular malignancies
M/c → Osteosarcoma

# STAGING

(I) QUIESCENT

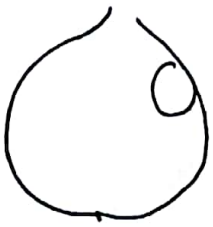

(II) GLAUCOMATOUS

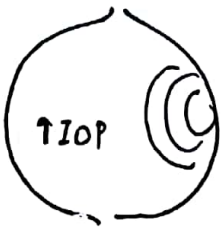


(III) STAGE EXTRAOCULAR EXTENSION

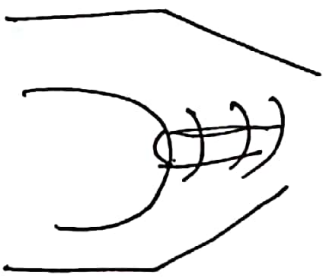

(IV) DISTANT METASTASIS

Rx –

1) Laser Photo coagulation
2) Cryotherapy

→ Can be used if $T_x \leq 3$ mm in height
→ Damage blood supply of $T_x$

3)

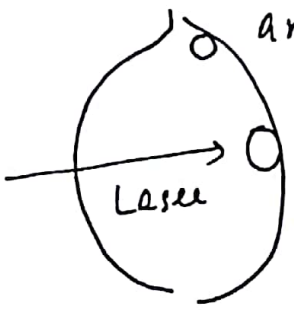


ant Lesions → Cryo

central Lesions
↳ Laser

3) Radiotherapy

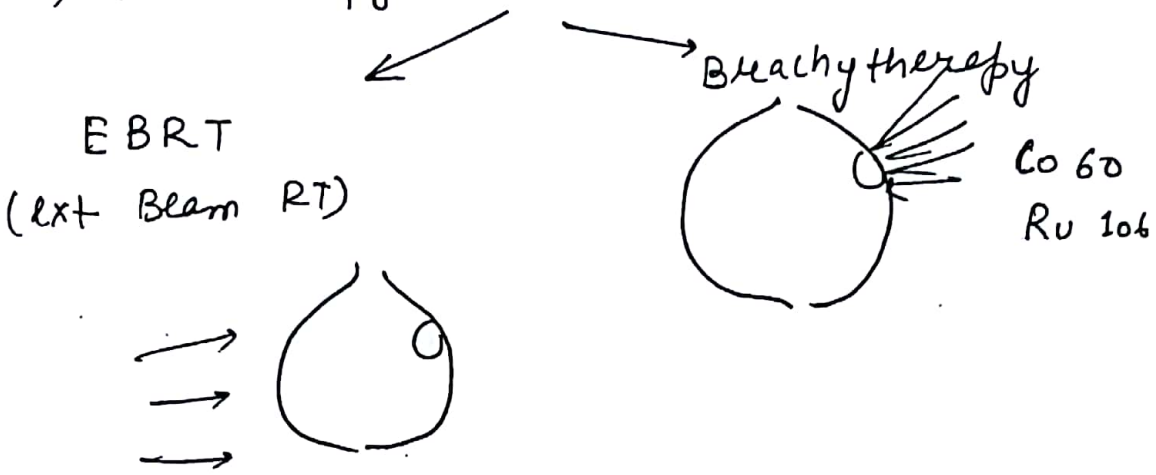


4) Thermotherapy

↳ thermal effect of diode is used to damage tumour.

5) Chemotherapy

Neoadjuvent role → ↓ size of Tx

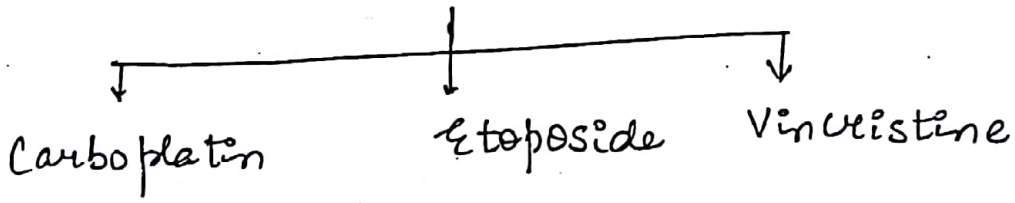


6) Surgery

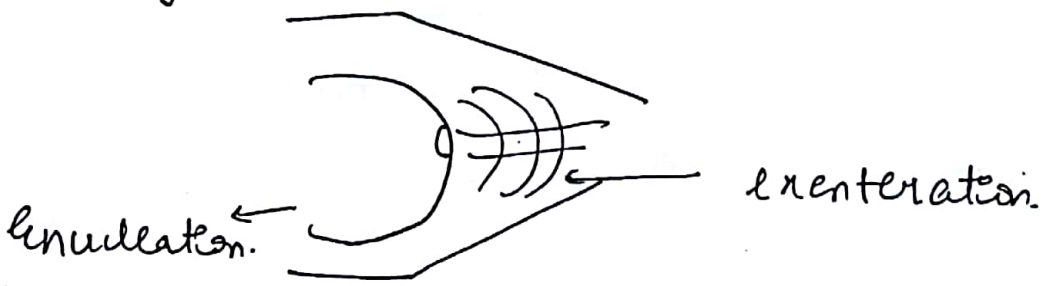

# SURGERIES TO REMOVE EYE

EXTRA - NOTE.

## IRON DEPOSITION

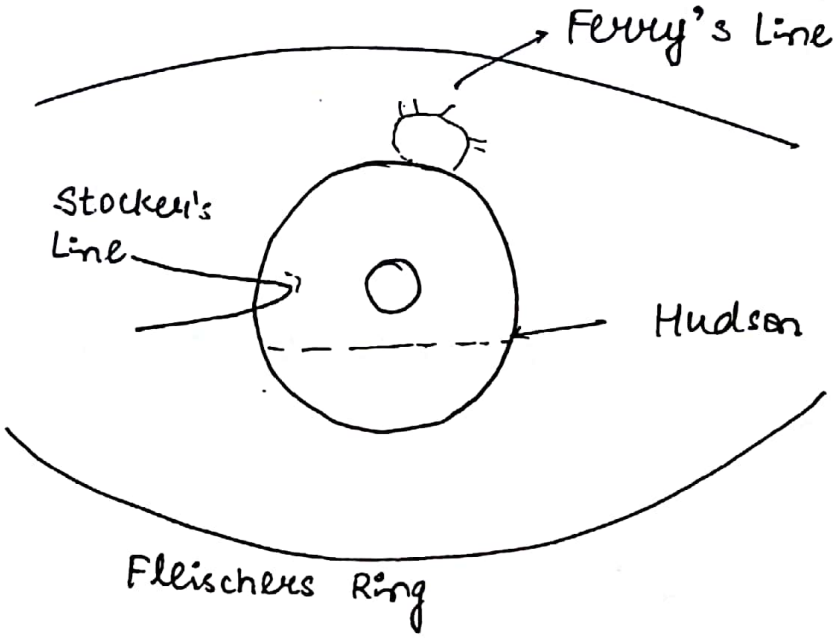


## ENUCLEATION

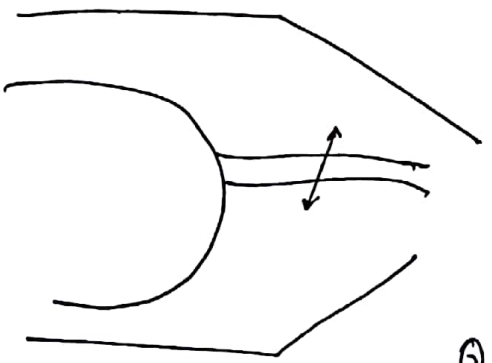

Enucleation = Removal of eyeball c max part of optic n/v

Q 10mm → 15mm (part removed)

↓

Q c in 10day / same sitting

Put Orbital Implant

↓ 6-8 wks Q

Prosthetic Eye

# EXENTERATION

→ Removal of all orbital contents

* Indication-

1> Tx

2> Mucormycosis






↓

Grafting for cosmetic reasons

## EVISCERATION




↓

If sclera is also inflammed → remove max part of sclera, leave a full a sclera

↓

Full Excision Q

Indication - Panophthalmitis

Artificial eye → prosthesis

## PANOPHTHALMITIS & ENDOPHTHALMITIS

D/D - endophthalmitis

| PAN | ENDO |
|---|---|
| Restricted ocular movement | No restriction |
| Other C/F - | Inflammation of inner coat of eye |
| → D/v | Retina, vitreous |
| → No fundal glow | Other features are same |
| → ~~Glow~~ Pain. | |

Rx = Intravitreal Antibiotic inj"

↓

Ceftazidime → Gram-ve

Vancomycin → Gram. +ve

Dexamethasone - very small dose to control inflammation

Antibiotic C/I Intra-vitreally -

Gentamicin ↔ Amikacin

↘ ↙

Maculotoxic

Antifungal → Intravitreally Given

↙ Amphotericin B

↘ Voriconazole

## BLOW-OUT #

Floor # due to Blunt Trauma

* Mechanism → BUCKLING effect

* C/F →

1) Periocular ecchymosis → BLACK EYE / PANDA EYE

| RACCON EYE → B/L seen # Base of skull |
|---|

2) ↓ sensation of affected cheek
↳ Damage to infra-orbital n/v.

3) Enophthalmos

4) Diplopia

5) Subcutaneous Emphysema
(if medial wall broken)

* Inv:-

1) X-Ray → Water's View / PNS

2) CT Scan →




White opacity against Black Background
= TEAR DROP SIGN

* Rx — Antibiotics + Anti-inflammatory × 10 days

- Enophthalmos, Deplopia improve
- No improvement in enophthalmos / Deplopia (M/s entrapment) → Surgery

# LIDS



## ANATOMY

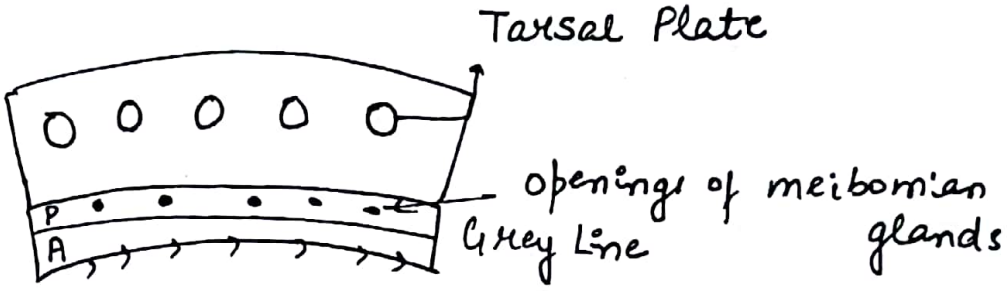


1. TRICHIASIS → misdirection of eyelashes.

2 POLIOSIS → Greying of eyelashes

3. MADAROSIS → Loss of eyelash → CAUSE: Chronic Blepharitis
" " eyebrows

CAUSES
Leprosy
Myxoedema

4. BLEPHARITIS –

Inflammation of Lid margin

- ANTERIOR
  - SQUAMOUS → Dandruff → Antibiotic + steroid → Lubricating
  - ULCERATIVE → ulcers below the scale (Staph. Infec") → Antibiotic oint.
- POSTERIOR → MEIBOMITIS

5) TYLOSIS –

Q Thickening of Lid Margin

6) ECTROPION –

Outward turning of Lid Margin

7) ENTROPION –

Inward turning of Lid Margin

8) HORDEOLUM EXTERNUM / STYE




→ Staph. Infection of ① Hair follicle of ② Gland of Zeis / ③ Gland of Moll

$R_x$ = ① Hot Fomentation

② Epilation

③ Oral anti inflammatory

④ Antibiotic ointment

9) HORDEOLUM INTERNUM

Acute inflammation of Meibomian Glands.



C/F - Painful swelling on lid

Rx - 1) Hot Fomentation
2) Oral antibiotics
3) Oral anti-inflammatories

10) CHALAZION -

→ Chronic Lipogranulomatous Inflammation of meibomian glands

→ Present as painless swelling

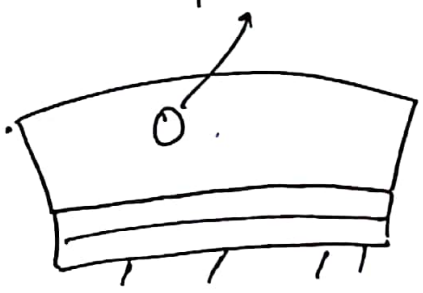

Rx = 1) Incision + Curettage
2) Intralesional Injec" of Triamcinolone acetate

Q. Recurrent Chalazion →

↙ M/c cause
Uncorrected mild refractive error

→ Q. Sebaceous cell carcinoma
↓
M/c site = upper lid.

Q. M/c malignant Tm of Lid = BASAL CELL CARCINOMA
↓
M/c site = Lower Lid
↓
Inner canthus

# 117 PTOSIS

Drooping of lid.

## TYPES

- NEUROGENIC
  - 1) III rd n/v palsy
  - 2) Horner's syndrome
  - 3) Synkinetic ptosis → Marcus Gunn Jaw-winking phenomenon → Aberrent connec" bet" LPS x Lateral pterygoid M/s (III M N/V & 5th n/v)
- MYOGENIC
- APONEUROTIC (M/C)
  - Dehiscence
    - Post-op
    - Involutional → old age
- MECHANICAL
  - 1) Lid Tm
  - 2) multiple chalazion
  - 3) conjunctival scarring

## MYOGENIC

- CONGENITAL
  - SIMPLE → Ptosis
  - BLEPHAROPHIMOSIS SYNDROME
    - 1) narrow palpebral fissure
    - 2) ptosis
    - 3) Cong. ectropion of lower lid.
- ACQUIRED
  - 1) Myasthenia Gravis
  - 2) Lambert Eaton Syndrome
  - 3) Ocular myopathies.

4) Telecanthus ( soft tenue
IPD - (N))

5) Epicanthus inversus -
↳ extrafold of skin on medial canthus is **Epicanthus.**
When arise from Lower Lid, it is called **Inversus**

## Rx of Ptosis -

**LPS RESECTION**
↓
Func" of LPs
↓
Upper Lid excertion (ULE)

~~From Lou~~
Distance from Lowermost to uppermost position of Lid after blocking Frontalis m/s

(N) = ≥ 12 mm

Min. req. for resection
↳ 4-5 mm

↓ SKIN route
Everbusch operation

↓ Conjunctival route
Blaskovics

**MULLERS RESECTION**
Fasanella-SERVAT Operation.

**SLING OPERATION**
Upper lid connected ī frontalis m/s
Fascia Lata
↳ Ideal material

## PURKINJE IMAGES

Images formed on refracting surface of eye

| I | II | III | IV |
|---|---|---|---|
| Ant. surface of cornea | Post. surface of cornea | Ant. surface of Lens | Post. surface of Lens |

Q. Images absent in aphakia = III, IV

Q. ☹ Image in Inverted = IV

Q. Pseudophakia → all 4 Purkinje images are +nt

## VISUAL ANGLES

### α angle

optic axis + visual Axis at nodal Point

### K angle

Pupillary Line + visual Axis at cornea

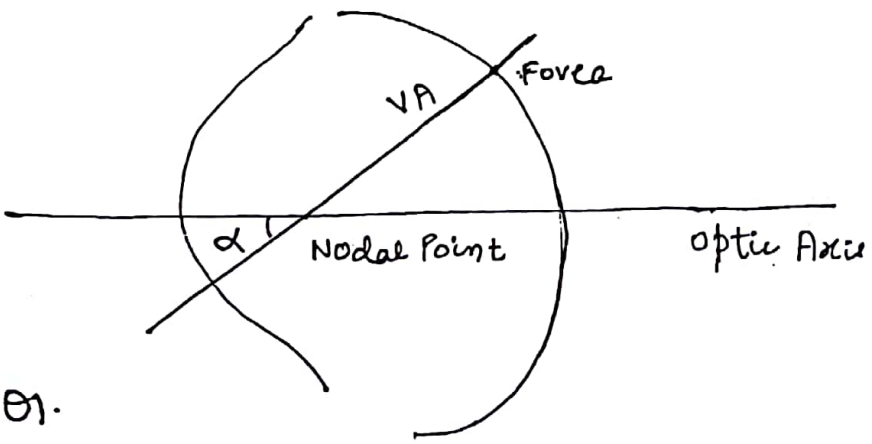


AIIMS Qn.

[The angular spacing betⁿ bars of C or E in snellen's chart in 1min for 6/6 letter

Largest letter when viewed from a distance of 6 meter, subtend an angle of 50 minutes in eye, bars of letter subtend 10 min]

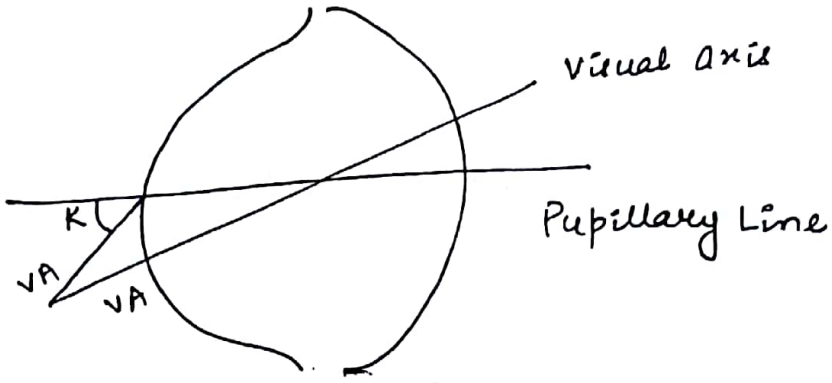


# REFRACTIVE ERRORS

## HYPERMETROPIA

1> Total Refractive Power is less than Required

2> Small eye

3> Light rays focussed behind Retina

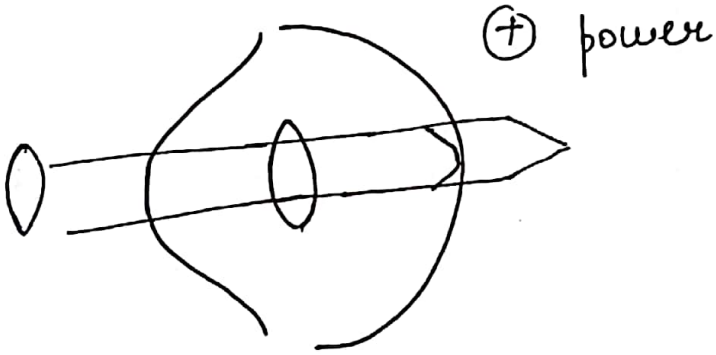


## MYOPIA

1> Total Refractive Power is more than required

2> Large eyes

3) Light rays focussed in front



## ASTIGMATISM

Difference of refractive power between 2 principal axis

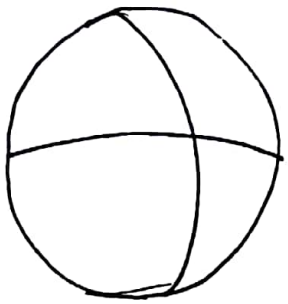

## ANISOMETROPIA

Difference of refractive power between 2 eyes of >2.5 D.

## ANISEKONIA

Difference of **Image size** between 2 eyes

5% is physiological + this helps us in depth perception.

But anything more than that is aniseKonia

It is measured by EIKONOMETRE

$R_x$ = ISEKONIC GLASSES

# CLASSIFICATION OF ASTIGMATISM

I>

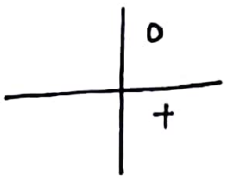


Simple HYPERMETROPIC

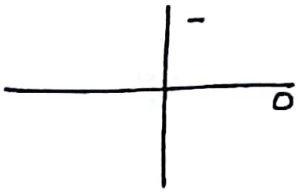


SIMPLE MYOPIC

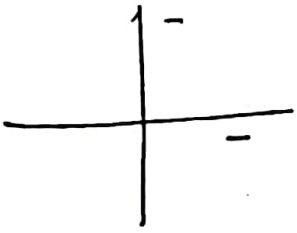


COMPOUND MYOPIC

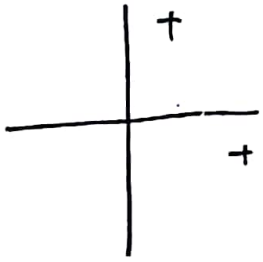


COMPOUND HYPERMETROPIC

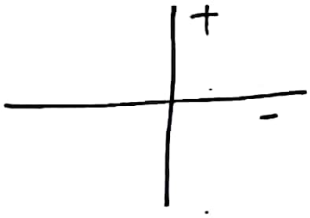


MIXED ASTIGMATISM.

II> According to Axis

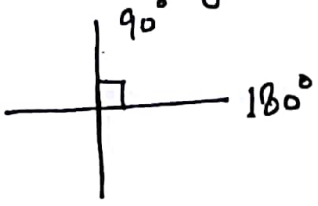


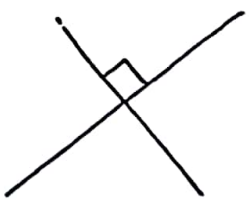

OBLIQUE ASTIGMATISM



BIOBLIQUE ACTIGMATISM

III)

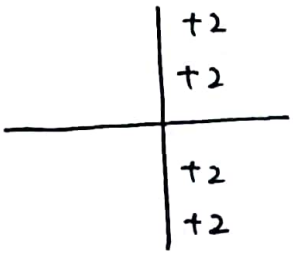


REGULAR
ASTIGMATISM

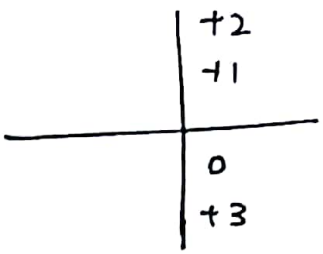


IRREGULAR
ASTIGMATISM

Keratoconus

IV) WITH THE RULE

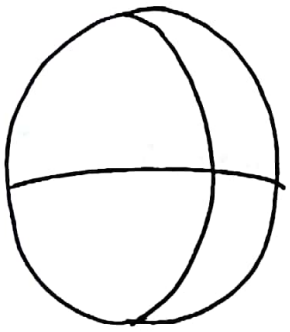

vertical more curved

AGAINST THE RULE

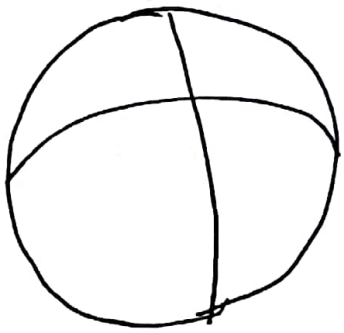

Horizontal more curved

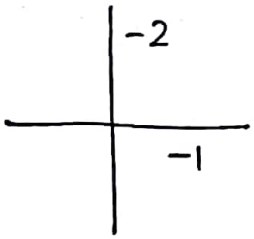


- means eye is myopic

↓

vertical more curved

↓

Hence ∴ the Rule

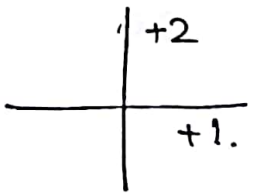


+ means eye is hyperimetropic

↓

vertical less curved

↓

against the rule

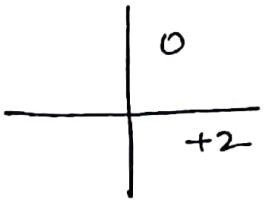


← Hypermetropic

vertical more curved
↓
c̄ the Rule

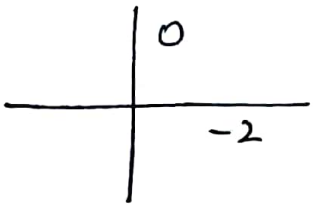


← Myopic

vertical less curved
↓
against the Rule

## APHAKIA

HIGH HYPERMETROPIA.

Rx

- Spects
- Contact Lens
- $\boxed{\text{IOL}}$ Rx OC Q.

Q. Choice of site of IOL implantation = Capsular Bag > Post. Chamber

Q only mydriatic c̄ no cycloplegic action = Phenyl - ephrine

Q. choice of cycloplegia in children = Atropine ointment (1%)
TDS x 3 days

Check for atropine fever
↳ stop the drug

SPECTS → +10 ⟶ +14 D

DISADVANTAGE -

1) Magnification ~ 30%

we can't correct uniocular aphakia c̄ spectes due to high anisekonia leading to diplopia

2) High spherical aberration

spherical aberration means refracⁿ from periphery is more than centres of lens.

↓

So, everything is PARABOLA

↓

PIN-CUSHION EFFECT

3) High Prismatic Effect

It leads to ROVING-RING SCOTOMA

↓

Q. JACK IN BOX PHENOMENON

(things nearby go out of vision due to narrow field of vision)

# RETINOSCOPY

CORRECTION FACTOR

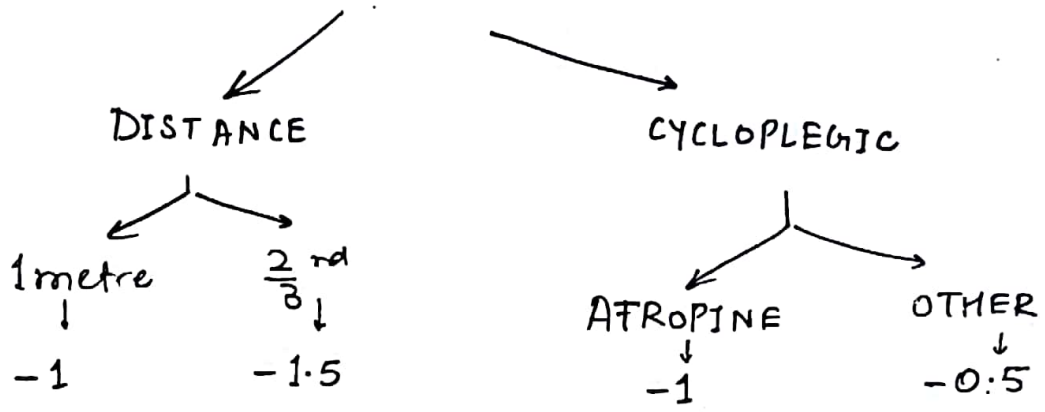


Add correc" factor to reading of retenoscopy

eg. If $\frac{+3}{+4}$, Dist. $\frac{2}{3}$rd, cycloplegic other than atropine

$\frac{+3\ -2}{+4\ -2}$ - $\frac{+1}{+2}$

At 1m. Movement Significance

With → Hypermetropia / Emmetropia / M < 1

Against → Myopia > 1

No movement → Myopia = 1

eg.

| |
|---|
| +1 |
| +2 |

Prescription

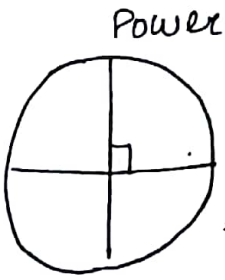


⇒ So, axis mentioned opp.

+1D spherical + 1D ~~cyclo~~ cylinder at 90°.

+2D spherical - 1D cylinder at 180°.

[spherical ~~gol~~ glasses give power to both axis.
So, by adding cylinder. we neutralize power].

| |
|---|
| +3 |
| +3 |

⇒ +3D spherical

| |
|---|
| +1 |
| 0 |

⇒ +1D ~~cyl~~ cylinder at 180°
-1D ~~at~~ cylinder at 90°

| |
|---|
| -1 |
| -1 |

⇒ -1D spherical

| |
|---|
| +1 |
| +2 |

⇒ +1D spherical +1D cylinder at 90°.
+2D spherical -1D cylinder at 180°.

| -5 |
| --- |
| -4 |

-4D spherical -1D cylinder at 180°

-5D spherical +1D cylinder at 90°.

## CONTACT LENS

- SOFT
- SEMI-SOFT or RIGID GAS PERMEABLE (RGP)

Q Hydroxyethyl Methacrylate (HEMA)

1> Silicone
2> Flouro-silicone

M/C infection after contact Lens = Pseudomonas

Soft contact lens used are more prone to. Acanthamoeba keratitis

TORIC LENS - Contact Lens i cylindrical correc" for astigmatism

- SOFT
- SEMI-SOFT

Q. C type of CL lens used in keratoconus = RGP

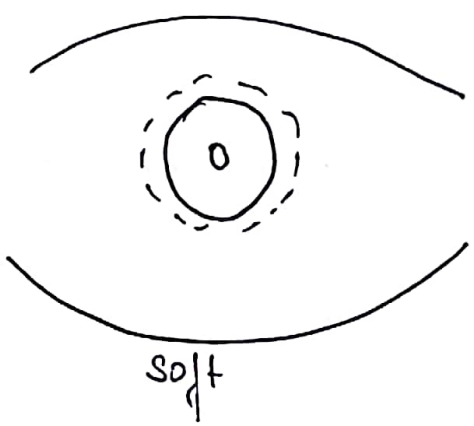


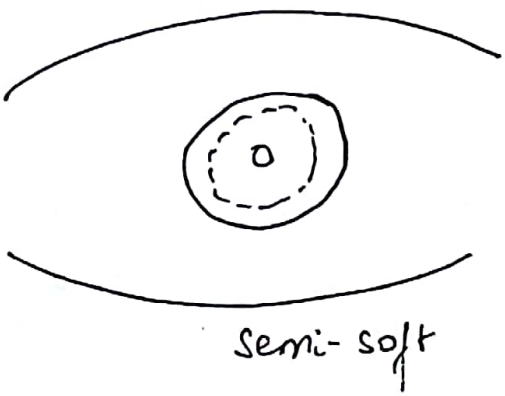

Higher the water content
Better is $O_2$ transmibility

## AMBLYOPIA

Partial Loss of vision ∴ no organic cause
also called LAZY EYE.

Vision < 6/6



PATHOLOGY Lies in LGB

C/F-
1) visual Acquity < 6/6
2) ↓sed contrast sensitivity

Q 3) Sunglass effect -
Brightness is less in effected eye

Q 4) Crowding phenomenon
skipping of nearby letters
A B CD

RxOC - QQ
1) Occlusion of (N) eye (4-6 hours/day)

Patching — Atropine
↓
PENALISATION

# BINOCULAR SINGLE VISION / FUNCTION

Difficulty of Brain to fuse 2 Retinal Images as 1

Q. Foveal Reflex formation = 5-6 months

Q BSV = 5-6 years.

Q. GRADES OF BSV

| (I) | (II) | (III) |
|---|---|---|
| Simultaneous Perception | Fusion | Stereopsis [DEPTH perception] |

## VISUAL PERCEPTION

- LIGHT SENSE
- FORM SENSE
  - Q visual acquity is a measure of Form sense
- CONTRAST SENSE
- COLOUR SENSE.

## DIPLOPIA Q

Double Vision.

(I) HORIZONTAL / VERTICAL / TORSIONAL

(II) UNIOCULAR / BINOCULAR

- UNIOCULAR → M/cc → Subluxation of Lens
- BINOCULAR → M/cc → Paralytic squint

UNIOCULAR

CAUSES

1) Incipient / Intumescent Cataract

2) Polycoria

3)

BINOCULAR

CAUSE

1) Thyroid ophthalmopathy

2) Blow out #

(III) CROSSED & UNCROSSED

UNCROSSED

False Image toward squinted eye

seen in convergent squint / Esotropia



Lateral Rectus Palsy
↓
convergent squint

CROSSED

False Image opposite squinted eye

Seen in Divergent squint / Exotropia



# ACTION OF MUSCLES

- HORIZONTAL
  - LR → ABduction
  - MR → ADduction
- VERTICAL
  - IS — SUPERIORS ARE INTORTERS
  - RAD — RECTI ARE ADDUCTORS

| | SR | IR | SO | IO |
|---|---|---|---|---|
| 1° Action | Elevation | Depression | Intortion | Extortion |
| 2° Action | Intortion | Extortions | Depression | Elevation. |
| 3° Action | ADduc" | Adduc" | ABduc" | ABduc" |

## YOLK M/S

Contralateral Synergists

- Q
  - ® Inf Rectus
  - Yolk M/s → (L) Sup. Oblique
- Q.
  - Dextroelevation

In outward deviated eye Action of elevation & Depression is of Recti.

- ® Sup. Rectus
- (L) Inf oblique

Levo depression -

Ⓛ Inf Rectus

Ⓡ Sup oblique

## HERINGS LAW

There is equal innervation in yoke M/s

## SHERINGTONS LAW

Equal / Reciprocal innervation in agonist + antagonist M/s



same. equal + Reciprocal

# STRABISMUS

Misalignment of eyeball.

- LATENT SQUINT (PHORIAS)
  - squint Δ by cover/uncover test
    - ESOPHORIA
    - EXOPHORIA
    - HYPERPHORIA
- MANIFEST SQUINT (TROPIAS)
  - CONCOMITANT
    - 1° Deviation = 2° Deviation
      - 1° Deviation: Deviation of squinted eye is 1° Deviation
      - 2° Deviation: Deviation of (N) eye behind the cover is 2° Deviation
  - INCONCOMITANT or PARALYTIC
    - 2° Deviation > 1° Deviation due to HERING'S LAW

## CONCOMITANT SQUINT

- ESOTROPIA
- EXOTROPIA
- ISOTROPIA

# ESOTRIA

- INFANTILE
- ACCOMODATIVE → Due to activation of accomodation reflex
- NON-ACCOMODATIVE

## INFANTILE ESOTROPIA

1) Manifests in 6 months
2) Angle of deviation is Large ~ 30 prism Diopters
3) Latent Nystagmus manifested by cover ~~con~~ Uncover test
4) Refractive error is (N) for age

## ACCOMODATIVE ESOTROPIA [Due to stimulation of accomodation]

- **REFRACTIVE**
  - High Hypermetropia that is uncorrected
  - ↓
  - Exerts excessive accomodation to compensate
  - ↓
  - Eyes converge
  - (N) $\frac{AC}{A}$
- **NON-REFRACTIVE**
  - → High $\frac{AC}{A}$ Ratio
  - → Refraction (N)
  - → No deviation for Distance
- **MIXED TYPE**
  - Hyperemetropia + High $\frac{AC}{A}$ ratio

## NON - ACCOMODATIVE

- STRESS INDUCED
- SENSORY DEPRIVATION In children
- DIVERGENCE INSUFFICIENCY
- Sx INCORRECTION

## EXOTROPIA

- CONGENITAL → very rare
- 1° → From 2 yrs of age
  - CONSTANT
  - INTER MITTENT
- 2° → sensory Deprivation of in adults
- CONSEQUETIVE → Sx overcorrecⁿ of esotropia

## PARALYTIC SQUINT

1> Diplopia

2> Confusion

3> Deviation
   2° > 1° [due to Hering's Law].

4> Restricted ocular movement

5> Compensatory head Posture.

# IV$^{th}$ N/V PALSY [Sup. oblique Paralysed]

FEATURES -

1) Hypertropia
2) Exycloterision
3) Vertical Diplopia worst on looking Down.
4) Limited depression in adduc$^{n}$
5) Compensatory Head Posture → Head tilt on opposite side Q.

**BIELCHOWSKY'S SIGN** Q

↳ Left Hypertropia

↓

Tilt the head toward (L) shoulder

↓

To Look straight eye has to intort

↓

Superior are intorters

↓

If S.O. Paly,
there is over working of SR

↓

↑ in Hypertropia

Hence, so Paly confirmed.

# VI$^{th}$ N/v PALSY [LR-6]

1> convergent esotropia

2> Defective AB duc" of affected side

3> ⓠ Horizontal Diplopia - worst in affected side

4> Face turned towards Paralytic side.

## MANAGEMENT OF SQUINT

1> HIRSCHBERG TEST :-

1 mm of Deviation of Light reflex = 7°

⇓

15 DD

Pupillary Border = 18° - 20°

At Limbus = 45°

2> KRIMSKY'S TEST/ PRISM BAR TEST-

Measure exact amount of squint in prism diopter



Prism Bar

3> COVER - UNCOVER TEST

4> ALTERNATE COVER TEST

PARALYTIC SQUINT

↳ wait for 5 - 6 months to improve

↓ If doesn't improve

**Squint Sx**

Undercorrecting → Resection.

Overcorrecting → Recession

CONCOMITANT SQUINT-

I> Refraction

↓

II> Check for amblyopia

Occlusion (if needed)

↓

Orthoptic exercises (if needed)

[Strengthening the convergence]

↓ - if nothing works

Squint Sx

## REFRACTIVE SURGERIES

- INCISIONAL
- LASER-ASSISTED (Lamellar)
- NEWER PROCEDURES

### INCISIONAL

1> RADIAL KERATOTOMY

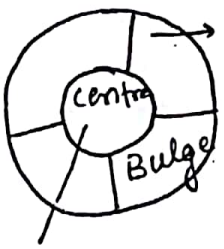


→ Radial cuts @ ē diamond at Periphery

Myopic → Best results are, 5D ē in

Centre flattening is to be done

## 2> ARCUATE KERATOTOMY / T-CUTS

Used to Rx astigmatism

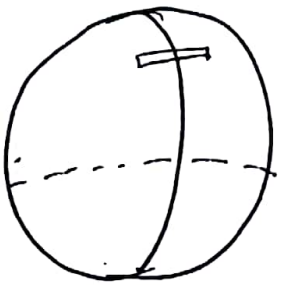

↓ cut on steeper axis

↓

that axis flattens on healing

↓

Compensatory curving on opposite axis

↓

Rx astigmatism by "COUPLING EFFECT"

If cataract

↓

astigmatism

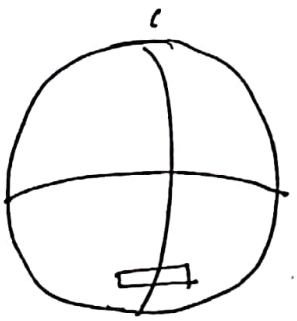


↓ the rule

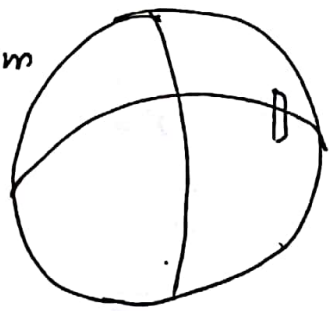


against the rule

## LAMELLAR / LASER ASSISTED

KERATOMILEUSIS - Changing corneal curvature

Laser used is EXCIMER ~~Ag F~~ (Argon F)

$\lambda$ = 193 nm

### PRE-REQUISITES :-

1> Pachymetry reading (N)

2> Age > 18yrs

3> Stable refractive error since last 6 months

4> Ant. Seg (N)

5> Fundus (N)

WORK- UP

1) Refraction
2) Pachymetry
3) Corneal Topography

## 1> PRK [PHOTO REFRACTIVE KERATECTOMY]

Remove the epithelium (painful)
↓
Apply Laser [dealing c superficial stroma]
↓
Bandage

DISADVANTAGE
- Painful
- Long Rehabilitation Time

## 2) LASIK [LASER IN SITU KERATOMILEUSIS]

Raise a flap → by micro keratome
└ by Femto laser
↓
Apply LASER [Deeper Stroma]
↓
Put the flap back

## 3> EPI-LASIK / LASEK [Laser Sub-epithelial Keratomileusis]

Raising epithelial flap
↓
Apply Laser [Sup. stroma]
↓
Put the flap back

} Done for Nebular opacity

S|E-

1) Dry Eye
2) Regression of No.
3) Sand of Sahara Syndrome
   ↳ infilteration of inflammatory cells b/w bed & flap.
4) Epithelial Ingrowth Bet" Bed & Flap
5) Infec" bet" Bed & flap
6) Febrous ingrowth Bet" Bed & Flap.

## NEWER PROCEDURE

1) SMILE Procedure → Femto laser.
   [Small Incision Lenticule Extraction]

   Procedure - Focus Femtolaser on stroma
   ↓
   cut the lenticule
   ↓
   Remove the lenticule through a small Incision

2) CLEAR LENS EXTRACTION-



Non-cataractous

To Rx → High Myopia

Retinal Detachment may occur if post capsule

## 3) PHAKIK IOL IMPLANTATION-

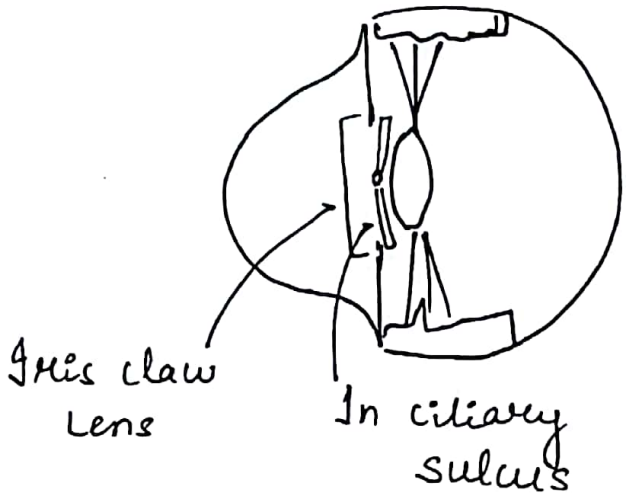


Cataract may develop if IOL touches Lens.

## 4) CONDUCTIVE KERATOPLASTY

Done in Presbyopia.

Ideal Pt-

- Emmetropic (N)
  2-2.5 D

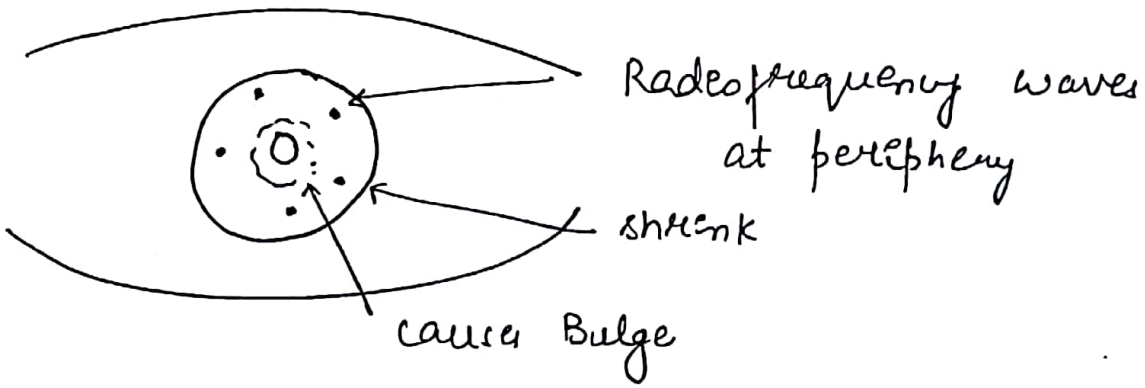


Based on Monocular Vision

So, untreated eye used for Far
treated eye used for near

# RETINA

Most SENSITIVE → FOVEOLA

THINNEST → ORRA SERRATA ( 0.1mm)

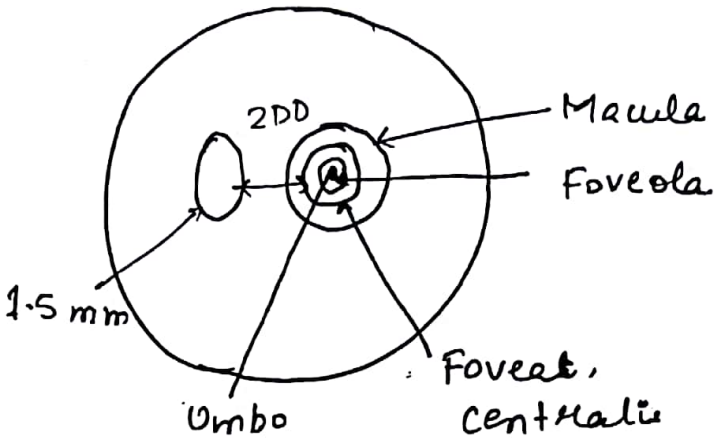


AMBLYOSCOPE / SYNAPTOPHORE
↳ Image.

## LAYERS OF RETINA

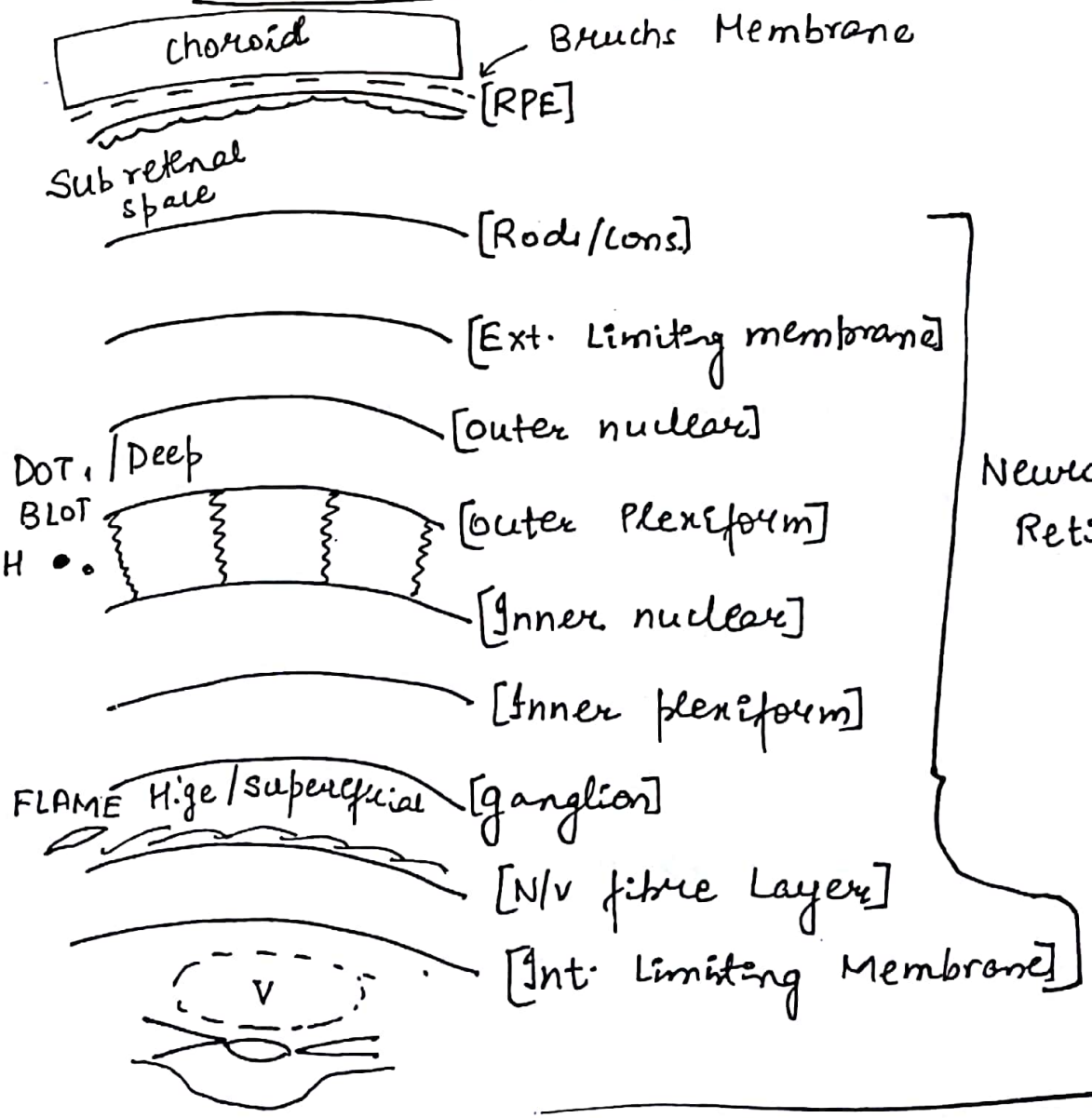

HARD EXUDATES → [Lipids]

SOFT EXUDATES → [Axonal Debris]

* SEQUENCE OF EVENTS IN RETINA [RETINITIS PROLIFERANS]

HYPOXIA

↓

↑sed capillary Permeability

↓

Leakage

↓

Oedema | Exudates | H'ge

↑↑↑ HYPOXIA

↓

Release of chemotactic factors

↓

Neovascularisation — NVD – at Disc; NVE → anywhere else

↓

Vitreous H'ge | Tractional RD | Neovascular Glaucoma

* ROLE OF PAN RETINAL PHOTOCOAGULATION —

Convert Hypoxia to Anoxia

## CHEMOTACTIC FACTORS

1> VEGF ( VASCULAR ENDOTHELIAL GROWTH FACTOR)

2> PDGF ( PLATELET DERIVE " ")

3) ILF ( INSULIN LIKE " ")

4) bFGF ( basic FIBROBLAST " ")

5) TNF-α (TUMOUR NECROSIS FACTOR)

6) TGF α/β ( TRANSFORMING GROWTH FACTOR)

Q. I.L. , Interferons are not related to angiogenesis → They are related to Inflammation

## INVESTIGATION

1> FUNDUS FLOURESCENE ANGIOGRAPHY (FFA)

Q. Inject dye in Antecubital vein

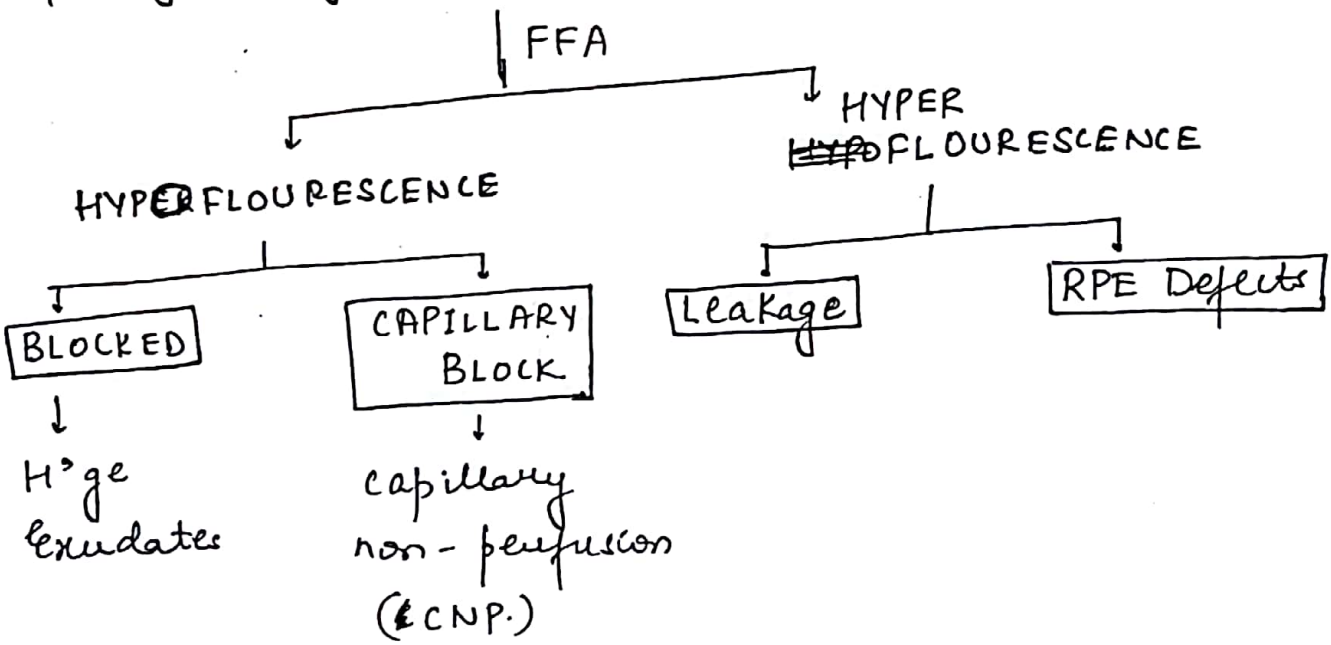

Q. ICG ANGIOGRAPHY

[Indocyanine Green.] – 98% bound to Plasma Protein.

specially used to study CHOROID. → stays for longer time

Q. ICG → particularly used for occult choroidal neovascularisation

## DIABETIC RETINOPATHY

Pathogenesis – Retinitis Proliferans.

PATHOLOGICAL CHANGES AT CAPILLARY –




1> Loss of Pericytes Q.

C/F-

STAGES

BACKGROUND (BDR) | PRE-PROLIFERATIVE | PROLIFERATIVE

1) Earliest feature
↳ Micro-aneurysm
↓
Inner nuclear Layer

BDR +

2> Hge, oedema, exudates

## PRE-PROLIFERATIVE

BDR
+
1> ↑↑↑ Cotton-Wool spots
2> Large Blot H°ge [venous Infarcts]
3> Looping & Beading of capillary

4> IRMA (Intra-Retinal Microvascular Ab(N))
↓
capillary shunt vessels

## PROLIFERATIVE

Pre-proliferative
+
Neovascularisation → NVD / NVE

(II)

- NPDR (non-proliferative)
  - MILD → Microaneurysm
  - MODERATE → BDR
  - SEV. → Pre-proliferative
- PDR (Proliferative)

Rx- 1) Glycemic control

2)

NPDR

check for CSMO

[Clinically significant Macular oedema]

edema — Hard exudates

[< 500 µm from centre of fovea]

FFA

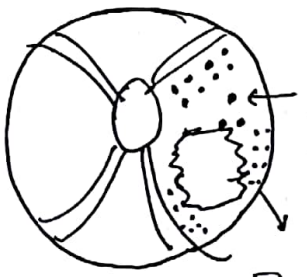

Focal Photocoagulation

Grid Photocoagulation

[2 rows along blood vessel

Few burns on temporal side]

PDR

PRP Laser

avoid macular area

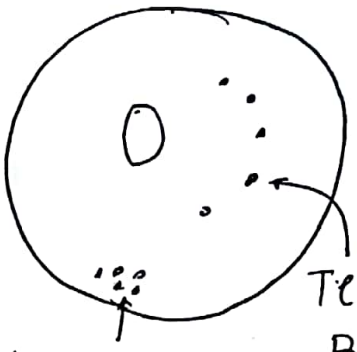

Temporal Barrage

Q Start Laser from inferior quadrant

Q. 2000 - 2500 Burns are given

Q. Most Imp factor for occurrence of Retinopathy in a diabetic patent- ⇒ DURATION (25-30yr)

Q. 2nd most Imp. factor ⇒ GLYCEMIC CONTROL.

Q. 1st Fundus exam" when ?

Type I → After 5 years

Type II → Immediately

Q. Frequency of follow-up

I → 1 yearly follow up

II ↙

Q Frequency of follow-up in ♀

↓

3 monthly follow up

(N) $\frac{\text{Artery}}{\text{Vein}} = \frac{2}{3}$.

## HTN RETINOPATHY

changes in retina due to long standing HTN

### KEITH-WAGNER GRADING

(I) Generalised attenuation of artery

(II) (I) + Focal Spasm

(III) II + H'ge + Exudates

(IV) III + Papilloedema

Q. Pt of PIH presents ∴ Hypertensive Retinopathy
(♀ Induced HTN)

# CENTRAL RETINAL VEIN OCCLUSION (CRVO)



## RISK FACTORS

1) HTN
2) Small eye (Hypermetropia)
   ↳ small Lamina cribrose
3) ↑ IOP
4) Blood viscosity Syndrome → Polycythemia / Leukemia

## PATHOGENESIS

| NON-ISCHAEMIC | ISCHAEMIC |
|---|---|
| ↓ | ↓ |
| Only Leakage | Retinitis Proliferans |

## C/F

| | NON-ISCHAEMIC | ISCHAEMIC |
|---|---|---|
| 1) | Visual Acquity ↓ | VA ↓↓↓ |
| 2) | Cotton wool spot | CWS ↑↑↑ |
| 3) | Pupillary RXN - (N) | RAPD |
| 4) | O/E | |

Multiple flame shaped H°ge

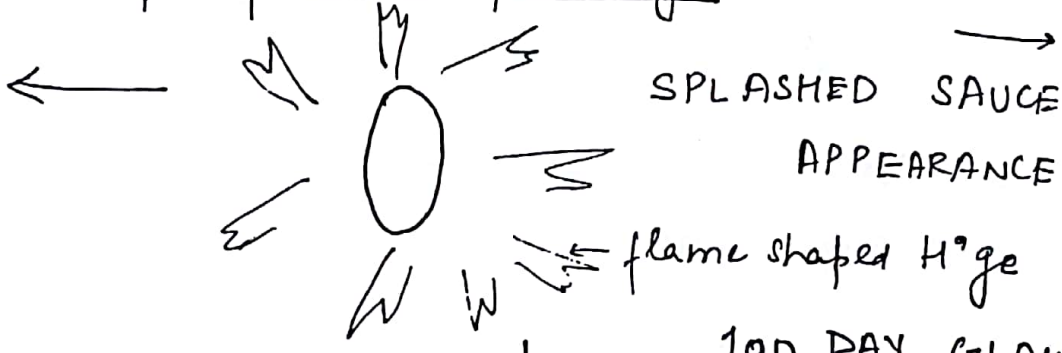


100 DAY GLAUCOMA ?
or 90 DAY

## INVESTIGATION-

1> FFA

- Non-Ischaemic → Leakages
- Ischaemic → Leak + Block (CNP)

## Rx-

- NON-ISCHEMIC → IVTA (Intravitreal Triamcinolone Acetate)
- ISCHEMIC → PRP

Monitor IOP

## CENTRAL RETINAL ARTERY OCCLUSION (CRAO)

↳ embolism occurs.

* RISK FACTOR-

A> 1) Heart Disease

2> Carotid artery Disease

B> Mucormycosis Q

AIIMS QQ

Cherry Red Spot + Hollenhorst plaque are seen in Both CRAO + BRAO.
But CRAO > BRAO.

* C/F-

1) Sudden painless loss of vision
2) Severe oedema → white retina
3) Marked attenuation of artery → thread like arteries
4) Interrupted blood column in brain

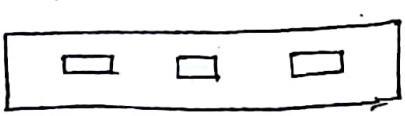

Cattle Track appearance of blood flow (VEINS)

5) cherry red spot

D/D of CHERRY RED SPOT

1> Berlin's oldema - Q AIIMS

2> CRAO ✓

3> Depositions ✓

a> Taysach's

b> Neiman Pick

c> Gaucher's

d> GM-1 Gangliosidosis etc all except

GM1 Gangliosidosis

I ⓧ

II ↓ cherry red spot

Q Pt. suffered from CRAO But not Blind ?

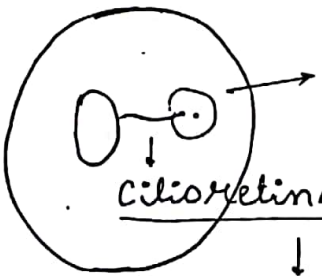

→ Tubular vision / Tunnel vision.

Ciliaretinal artery

↓

Branch of short post. ciliary artery

Rx -

AIM of Rx → Dislodge to emboli

↓

Sudden ↓↓ of IOP

↙ I.V. ACETAZOLAMIDE

↘ OCULAR MASSAGE

## CAUSES OF TUNNEL VISION

1> B/L OCCIPITAL LOBE LESION
2> CRAO = cilioretinal artery
3> Late stage of RETINITIS PIGMENTOSA
4> QUININE TOXICITY

## RETINITIS PIGMENTOSA

1> Dystrophy of [Rods] & Cones (Photoreceptor cell)
↓
primarily affected

2> Genetic Disease & can be

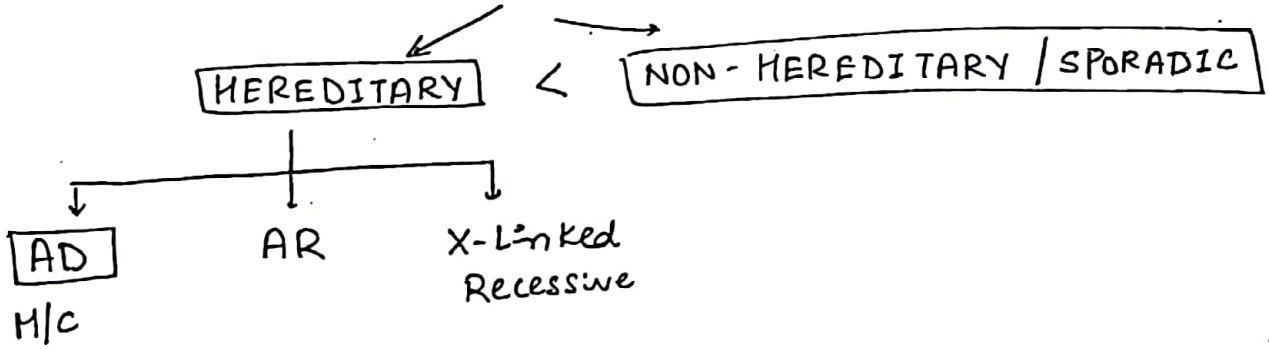


3> C/F → Nyctalopia

4> O/E -

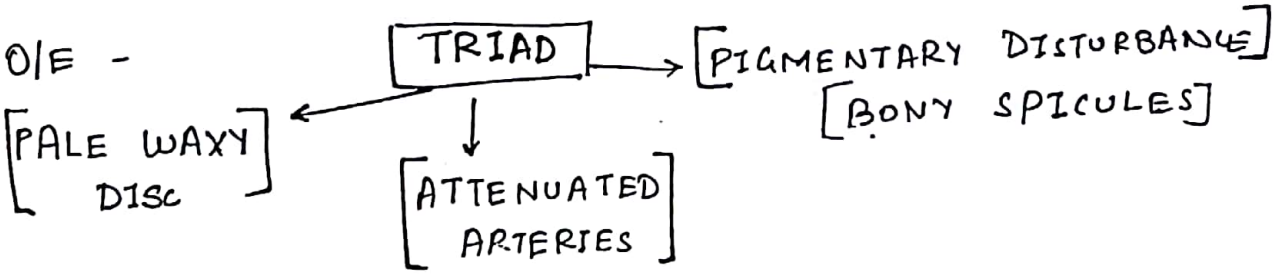


5) INV

a> Perimetry → 1st involves mid periphery

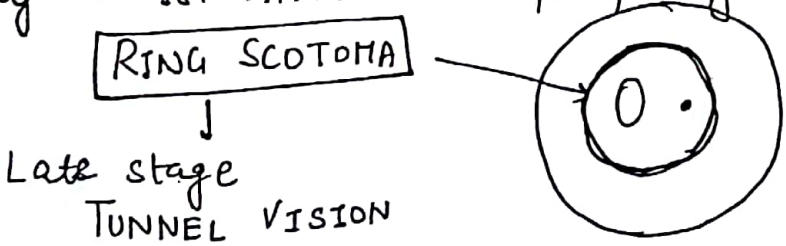

b> **ERG (Electro Retino Gram)**

It tells the activity of outer 2 layer of Retina

Rods + Cone → outer nuclear → Bipolar cells + Muller cells

Q.

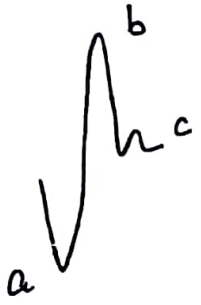


a = Rods + cones

b = bipolar + muller cells

c = RPE.

In Retinitis Pigmentosa ⇒ ↓ amplitude of a + b waves

## ATYPICAL RP.

1> SECTORAL RP

Better Prognosis than a typical case

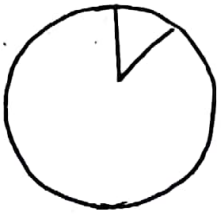

2> PERICENTRIC RP / INVERSE RP

starts from centre

3> RP SINE PIGMENTO

NO Bony Spicule

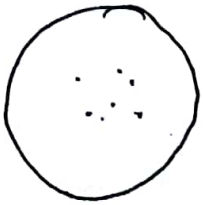

SALT + PEPPAR Fundus

4) RP ALBESCENS



White spots

# SYSTEMIC ASSOCIATION

1) Q. USHERS SYNDROME – M/C
RP + Deafness
Rx = no effective Rx
Vit A for rods
Vit E as an anti-oxidant

2) BEST Disease / BEST VITELLYFORM DYSTROPHY
→ AD
→ childhood disease
→ Dystrophy of RPE
→ O/E – Macula – egg yolk Appearance
Q EOG – Ab (N)

## ELECTRO-OCULO-GRAM

Measures standing potential of eye.

Q. ARDEN RATIO = $\frac{\text{Light Peak}}{\text{Dark Trough}}$ $\geq$ 1.85. (N)

In BEST DISEASE = < @ 1.5

# CENTRAL SEROUS RETINOPATHY (CSR)

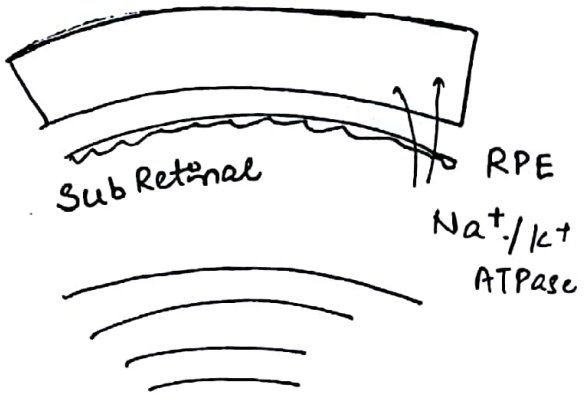


## PATHOGENESIS

Weakening of $Na^+/K^+$ ATPase Pump of central Retinal Pig. Epithelium

↓

Collection of fluid in Sub-Retinal Space

↓

Causing shallow Retinal Detachment

↓

CSR

## C/F -

Q1> young ♂

Q2> Self-Limiting

3> Disturbance of vision

- Metamorphopsia (Distortion of image)
- Micropsia (small)

4> O/E

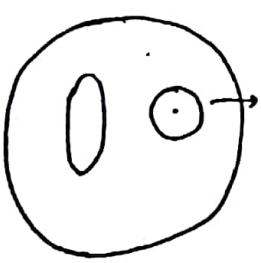

Ring Reflex = Ring of light encircling detached Retina

5> Inv :- (I) FFA QQ

Ink-Blot appearance



Smoke-stack appearance



(II) AMSLER-GRID TEST

→ Piece of paper ē a central dot
→ Pt can tell if any disturbance of vision.

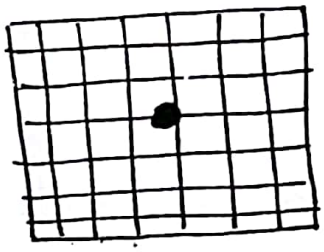

6> $R_x$ – not Required steroids c/I ⇒ aggravate CSR

CYSTOID MACULAR OEDEMA

CAUSES

I> INFLAMMATORY-
all causes of Intermediate & Posterior Uveitis

II> VASCULAR CAUSE-

III> DEGENERATIVE
Retinitis Pigmentosa

IV> IRVINE GASS SYNDROME
CME after cataract $S_x$ as a post-op complication

C/F-

1> Diminution of vision

2> O/E → Dull or absent foveal Reflex

3>

Inv-

1> FFA

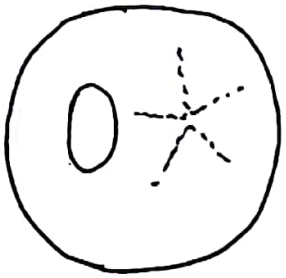

→ FLOWER-PETAL PATTERN

↓

outer plexiform is layer is Radially present ⇒ HENLE's Layer

↓

So, leakage is Radial

Rx-

1) Oral Acetazolamide

2) Topical NSAIDs-
Indomethacin.

## PUTSCHER's RETINOPATHY

ETIOLOGY

Q. 1> Pancreatitis → acute

Other causes-

- Head Trauma
- Chest ,,

PATHO

Air/ Fat embolism



multiple cotton wool spot

$R_x$ - no effective $R_x$.

## BULL'S EYE MACULOPATHY

Alternate areas of hyper · hypo pigmentation



ETIO-

1) Chloroquine
2) Hydroxychloroquine
3) Cone Dystrophy
4) Batten Mayo Syndrome / Battens Disease
   ↓
   cerebro-macular degeneration.

## PATHOLOGICAL MYOPIA

Any Myopia ± fundus changes

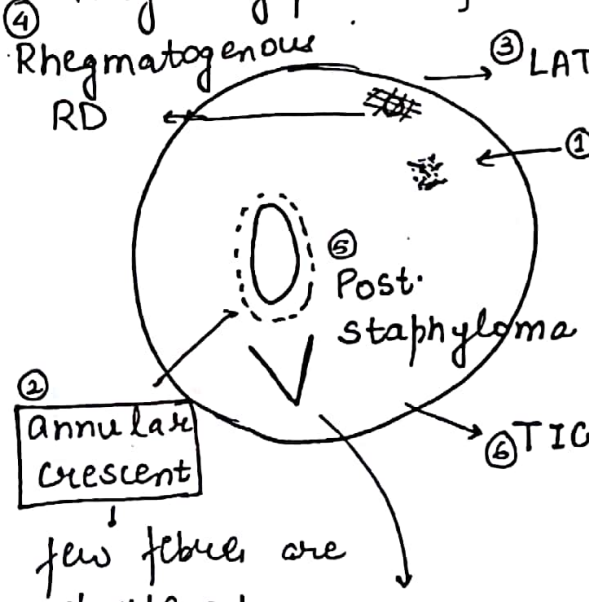


few fibres are shortened

# RETINAL DETACHMENT

Separation of RPE from Neurosensory Retena

## TYPES

H/C
1> TRD (Tractional RD)
2> RRD (Rhegmatogenous RD)
3> ERD (Exudative RD)

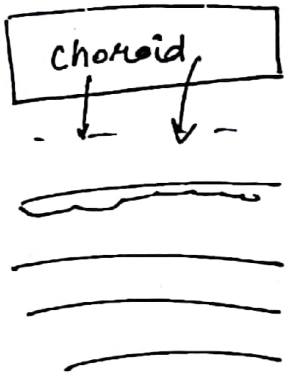


## RHEGMATOGENOUS RD

TYPE

HOLE → After Degeneration → LATTICE DEG. / SNAIL-TRACK DEG.

TEAR → Traction
H/C- Post. Vitreous Detachment

C/F :-

1> D/V
2> Visual field Defects
3> Floaters → opacities in vitreous cavity
4> Photopsia → flash of light seen by pt. due to traction on Rods / Cones

57 GREY REFLEX

Look grey due to detachment

$R_x$ -

① TRD → 1) PRP
2) $S_x$

② ERD → $R_x$ the cause

③ RRD → Close the break

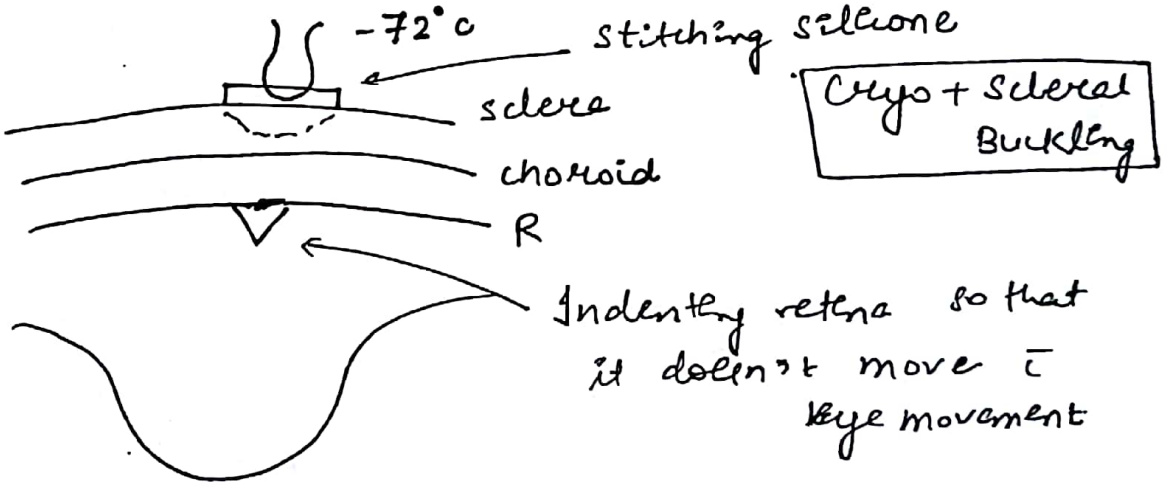


## RETINOPATHY OF PRE-MATURITY (ROP)

PATHO

Free Radical Injury to developing blood vessel

↓

Hypoxia

↓

Retinitis Proliferans

C/F -

STAGE 1 → Demarcation Line

STAGE 2 → Ridge formation

STAGE 3 → Neovascularisation

STAGE 4 → Subtotal RD

STAGE 5 → Total RD

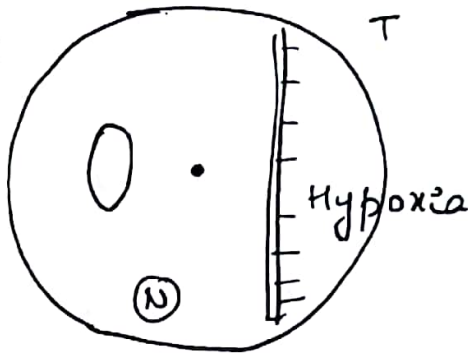


## Rx OF ROP -

Q. Laser Photo-coagulation of Hypoxic Pts.

## PROPHYLAXIS -

1) Vit E Therapy

Q. C factor is more Imp for occurence of ROP?
⇒ Prematurity

Q. Ideal Time of screening for ROP?
Add 4 weeks to Post natal age (31-33 wks)
Later.

THRESHOLD RETINOPATHY → other name of ROP.

CRITERIA -

| STAGE | ZONE | EXTENT | PLUS DISEASE |
|---|---|---|---|
| III & Above | 1,2 | 5 contigous or 8 non-contiguous clock hours | Tortuosity of artery & Vein |

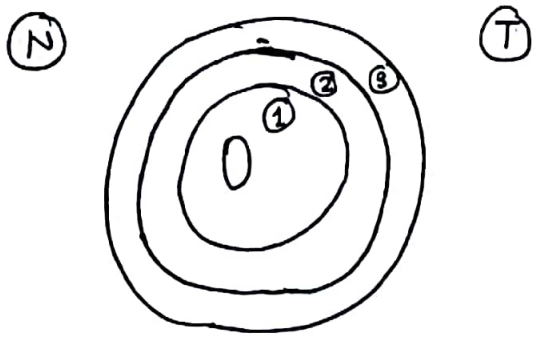


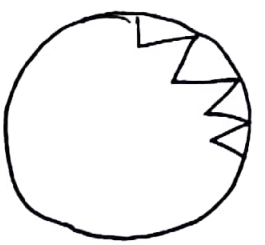

Contiguous

# AGE RELATED MACULAR DEGENERATION (ARMD)

→ Choroidal Disease

→ Degenerative changes at macula in old age
↳ irreversible loss of vision

M/c **DRY** (80-85%)
(Non-Exudative)

**WET**
(Exudative)

1> 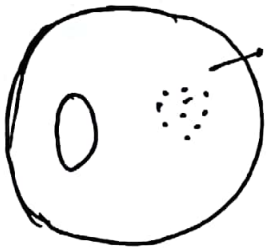

DRUSENS

2> 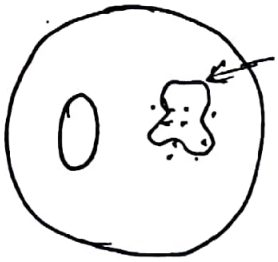

Geographical atrophy

No effective Rx

1> RPE Detachment



RPE

2> Choroidal / Subretinal neovascularization

Rx

- SUBFOVEAL — Below
- JUXTAFOVEAL — Beside
- EXTRA FOVEAL — away from → Laser Photo coagulation

Rx

I → Intravitreal Inj^n of Anti-VEGF

II

III

Bevacizumab → Avastin

Ranitizumab → Lucentis

Q ② Photo dynamic Therapy
↓
Verteporfin
+
Diode y

} Hypopigmentation or whitening of the area occurs immediately after PDT

③ TTT ( Trans- Pupillary Thermotherapy)
↓
Thermal effect is used to damage the membrane

## VITREOUS

| 1° | 2° | 3° |
|---|---|---|
| ↓ | ↓ | ↓ |
| Hyaloid Tissue (formed during embryonic life) | Q Hyaluronic Acid + Type II collagen (Adults) | Q Zonules of Zinn / Suspensory Ligaments |
| ↓ | | |
| MESODERM | NEURO- ECTODERM | |

Q Strongest attachment to ▼ retina
↳ At Vitreous Base
( ora serrata)

Q. C is more in vetreous?
Ascorbate
V:P = 9:1

# FLOATERS

Opacities in vitreous

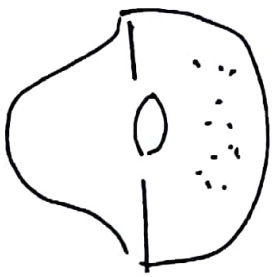

1) Inflammatory cells
2) Pigments
3) H'gic clots
4) Synchisis Scentillans
   └ Cholesterol Bodies
5) Asteroid Bodies
   ↳ asteroid hyalosis

Q
a) Disease of old age
b) ♂
c) ~~Bb~~ VA (N)
d) Ca + Lipids
e) A/c DM, HTN, high cholesterol,
f) Hypermetropia
Qf) Not associated c myopia

6) MUSCAE VOLITANTES-
Remnants of Hyaloid Tissue

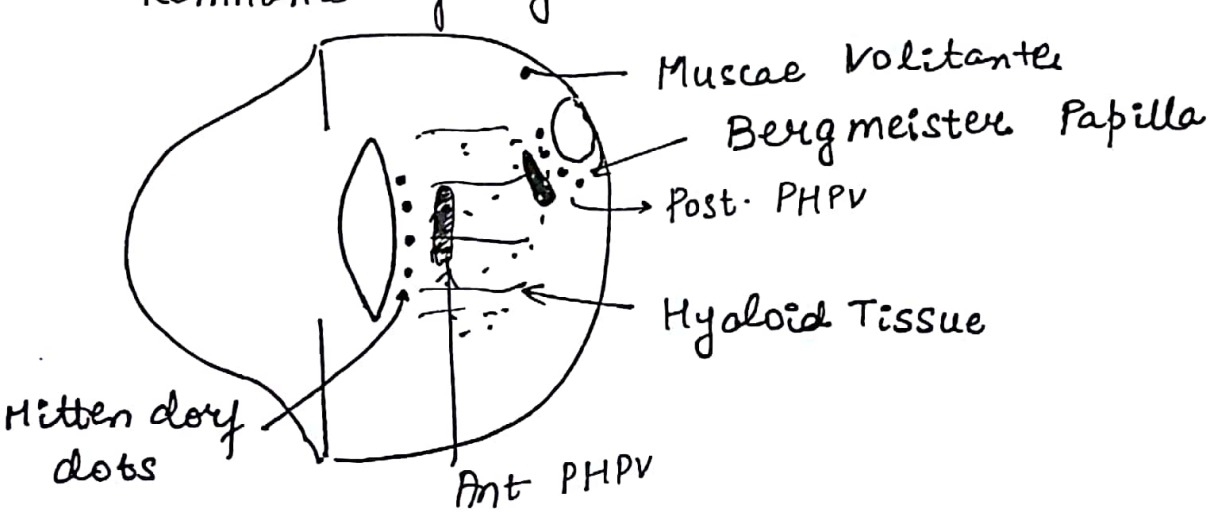

Ant PHPV → Better Prog than Post. PHPV.

PHPV

♀ ← → ♀

associated ē Microphthalmos

No calcification

# COMMUNITY OPHTHALMOLOGY

Q M/cc of Blindness in India = CATARACT

Q M/cc of Preventable Blindness = 1) CATARACT
2) Trachoma

Q M/cc of childhood Blindness in India Vit A Def

Q 2nd M/cc of Blindness = Refractive Error (RE)

Q M/cc of ocular Morbidity = RE

Q M/cc of Blindness in world = Cataract

Q. M/cc of Blindness in developed countries = Glaucoma
↓
ARMD

Q Define Blindness → WHO
NPCB
Legal

Best corrected visual acquity in Better eye < 3/60 (BCVA)
or
visual field ( Better eye)

Q. BCVA < 6/60 . NPCB Def^n
< Better eye

Q Prevalence of Blindness in India = 0.56%
(>50yrs = 1.1%

Q. Incidence of Cataract in India = 62.6%

Q School Screening Programme

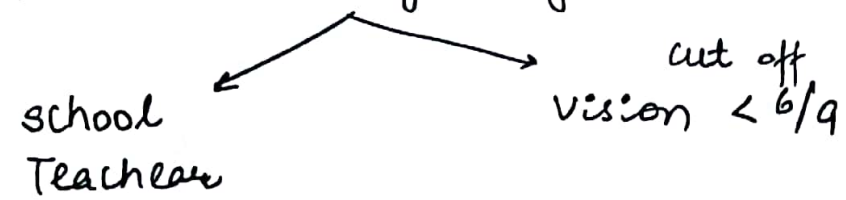


VISION - 2020

Q Ophthalmologist : Population 1 : 50,000

Q. 2° service centre : Population 1 : 5 lakh